

Experimental identification of the actinosporean stage of *Sphaerospora renicola* Dykova & Lom 1982 (Myxosporea: Sphaerosporidae) in oligochaete alternate hosts

K Molnár,¹ A El-Mansy,² Cs Székely¹ and F Baska¹

¹ Veterinary Medical Research Institute, Hungarian Academy of Sciences, Budapest, Hungary

² National Institute of Oceanography and Fisheries, Cairo, Egypt

Abstract

The extrapiscine development of *Sphaerospora renicola*, a myxosporean parasite of the kidney of common carp, *Cyprinus carpio* L., was studied in the experimentally infected oligochaetes *Tubifex tubifex* (Müller) and *Branchiura sowerbyi* (Beddard). After the infection of these tubificids with homogenized common carp kidneys containing myxospores of *S. renicola*, the development of actinosporean stages was first observed under light microscopy 8 days after infection in pathogen-free *T. tubifex*. Infection of *B. sowerbyi* with mature actinosporean stages was first observed 91 days after infection. At that stage of development, pansporocysts containing neoactinospores filled the intestinal epithelium of the worm. Ninety-five days after infection, pansporocysts containing actinospores and free actinospores were found in the gut lumen of *B. sowerbyi*. Actinospores of *S. renicola* emerged from *B. sowerbyi* after 98 days of intraoligochaete development. These were floating in the water and showed the typical form of neoactinospores. The shape of the spores was triangular in apical view and elliptical in lateral view. The prevalence of infection reached 37%. Control specimens of *B. sowerbyi* proved to be free of neoactinospores. Except for a single specimen of *B. sowerbyi*, the only early developmental stages (pansporocysts) were found in *T. tubifex*.

Correspondence Dr K Molnár, Veterinary Medical Research Institute, Hungarian Academy of Sciences, H-1581 Budapest, PO Box 18, Hungary

Introduction

Wolf & Markiw (1984) proved that the extrapiscine development of *Myxobolus cerebralis* took place in oligochaete alternate hosts acting as the site of development for triactinomyxon stages earlier classified into the Actinosporean class of the Myxozoa. Since then, several experiments have demonstrated that actinosporean spores developing in oligochaetes infect fish and cause myxosporean infections, while myxosporean spores start their development exclusively in oligochaetes. Successful experimental studies have been conducted on several myxosporeans (El-Matbouli & Hoffmann 1989, 1993; Ruidisch, El-Matbouli & Hoffmann 1991; Styer, Harrison & Burtle 1991; El-Matbouli, Fischer-Scherl & Hoffmann 1992a; Grossheider & Körting 1992; Benajiba & Marques 1993; Kent, Whitaker & Margolis 1993; Yokoyama, Ogawa & Wakabayashi 1993, 1995; Uspenskaya 1995; Trouillier, El-Matbouli & Hoffmann 1996; Bartholomew, Whipple, Stevens & Fryer 1997; Yokoyama 1997; El-Mansy & Molnár 1997a,b; El-Mansy, Molnár & Székely 1998a). A detailed ultrastructural study of different actinospores was first carried out by Lom, Yokoyama & Dyková (1997b).

Sphaerospora renicola is an important parasite of the common carp, *Cyprinus carpio* L. The developmental stages of this species are the causative agents of swimbladder inflammation, a disease characterized by high pathogenicity. The development of carp sphaerosporosis (*Sphaerospora renicola* syn. in part with *S. angulata*) has been elucidated mostly by Hungarian researchers (Csaba 1976; Molnár 1980;

Csaba, Kovács-Gayer, Békési, Bucsek, Szakolczai & Molnár 1984; Molnár 1988a,b), who first detected the occurrence of sporogonic stages in the kidney of carp in Europe, described the blood and swim-bladder stages, and performed experimental transmission of the extrasporogonic stages. Studies carried out by other researchers (Körting 1982; Lom, Dyková & Pavlasková 1983; Odening, Walter & Bockhardt 1989; Voronin & Chernysheva 1993) provided a more detailed insight into the nature of sphaerosporid infections in fish, but only scarce information was available on extra-piscine development.

The present paper reports on the experimental infection of the oligochaetes *Branchiura sowerbyi* (Beddard) and *Tubifex tubifex* (Müller) with *S. renicola* spores collected from common carp, which was followed by the development of actinosporean stages belonging to the neoactinomyxon type in these oligochaetes.

Materials and methods

The kidneys of three *S. renicola*-infected common carp fingerlings served for the infection of oligochaetes.

Two species of oligochaetes were used in the experiments. *Branchiura sowerbyi* were collected from the mud of a fish pond where common carp were not cultured, cleaned, and then examined for the presence or absence of actinosporean infection during a one-year laboratory survey (El-Mansy *et al.* 1998b). The rest of these oligochaetes were maintained alive in an aquarium for 4 months until the start of the experiments. Specimens of *T. tubifex* were collected from a muddy pool near the top of a hill where no fish could be found. The *T. tubifex* were transferred into sterilized mud and propagated in the laboratory in aerated aquaria. The oligochaetes were identified according to Brinkhurst (1963). These were fed on granulated fish food and pieces of chicken faeces were added to increase the organic matter content of the mud. Normal tap-water was used throughout the experiment. The temperature of the room varied between 18 and 22 °C. The *T. tubifex* specimens used for the experiments were considered parasite free, but the *B. sowerbyi* specimens harboured a natural actinosporean infection from the pond farm. The experiment started on 1 August 1996.

Two types of containers were used in the experiments. A proportion of the oligochaetes were

placed into a small aquarium containing 5 L of water, while others were placed into a small plastic cup of 500 mL volume. All containers were continuously aerated and regularly supplied with fresh water to prevent evaporation and to refresh the water for the oligochaetes. The aquarium contained about 200 *B. sowerbyi* and more than 200 *T. tubifex*, while in the small cup, there were \approx 30 *B. sowerbyi* and 50 *T. tubifex*. Homogenized kidneys of common carp fingerlings containing thousands of *S. renicola* spores were mixed into the mud in the containers. An aquarium and a small cup containing the same number of oligochaete specimens from the same stocks were used as controls.

The release of actinosporean stages was checked regularly after placing 24 *B. sowerbyi* and 36 *T. tubifex* and the same number of control specimens into 2-mL cell-well plates three times a week (Yokoyama, Ogawa & Wakabayashi 1991). After one day of incubation, the water in the wells was checked for the release of actinosporean spores under a microscope. Some of the worms were also placed onto a slide under a coverslip and examined for the presence of developmental stages. (After microscopic examination the cell-well plates were put back into the incubator and re-examined several times at least for 3 months, while only the water in the wells was refreshed). Every second day, water from the aquaria and the cups was filtered through a 10- μ m mesh. The filtrates were placed in a drop of water and examined for the presence of actinosporean stages. Every week, the *T. tubifex* found to be infected by microscopic examination were sacrificed for histology. By week 7 post-infection, a total of 14 *T. tubifex* specimens had been fixed in Bouin's solution, embedded in Paraplast wax (Paraplast^R Monoject Sci. Inc., Ireland) cut into 4–8- μ m-thick sections, and stained with haematoxylin and eosin (H&E). Unfortunately, because of a technical failure, no histological preparations were available from specimens fixed between weeks 5 and 7. Only four *B. sowerbyi* specimens were fixed for histology at 91 and 95 days after infection. On day 95, two infected *B. sowerbyi* were fixed in 2% osmium tetroxide for electron microscopy, washed several times with cacodylate buffer, dehydrated and embedded in Durcupan ACM resin. Semithin sections (0.5–1 μ m) were made and stained with 0.1% methylene blue solution. Ultrathin sections were cut with glass knives, contrasted with uranyl acetate and lead citrate, and examined with a JEOL-100 transmission electron microscope.

Neoactinomyxon stages released from oligochaetes were examined under a coverslip. These were recorded on videotapes with the help of a video image program, as described by Székely (1997). Photos were taken, drawings made and measurements recorded. The actinosporean stage of *S. renicola* was described using the terminology of Janiszewska (1957) as modified by Lom, McGeorge, Feist, Morris & Adams (1997a).

Results

Light microscopy

Intraoligochaete actinosporean developmental stages in worms under a coverslip could only be studied in the thin and transparent *T. tubifex* specimens. *Branchiura sowerbyi* specimens were too thick to allow a study of infection. Developmental stages were found in the gut epithelium of some segments of *T. tubifex* from both the aquarium and the small cup. These stages increased in number and size over time, and an increasing number of segments became infected. The infected intestinal segments differed from the uninfected ones by their darker colour and thickened walls. The first sign of infection in living *T. tubifex* was recorded 8 days after infection. The last infected specimen was found 49 days after infection. Altogether, 14 out of the 36 *T. tubifex* specimens examined from the infected stocks harboured these stages. No infection was recorded in control *T. tubifex*.

In the less transparent *B. sowerbyi* specimens, light microscopy first revealed an intensive infection with actinosporean stages 91 days after experimental infection. The stages detected at that time were mature pansporocysts. Actinospores were first released from *B. sowerbyi* 98 days after infection and the presence in the water of the spores was recorded for one week later. During that period, typical neoactinospores were continuously released from worms into the water of the cell-well plates. Nine out of the 24 *B. sowerbyi* specimens examined in cell-well plates released neoactinospores, in consistently high numbers. During the 3-month incubation period preceding the release of neoactinospores, some aurantiactinospores were occasionally detected in two wells and low numbers of raabeia spores in one other well. No neoactinospores were found in the controls, but as in the infected stocks, one worm released some aurantiactinospores and another some raabeia spores.

No actinospores were found in the water of the cell-well plates harbouring the rest (22) of the *T. tubifex*. Similarly, no actinosporean infection was found in cell-well plates containing the control stocks of *T. tubifex*. In one well of a cell-well plate where 10 *T. tubifex* were transferred from the infected plastic cup 102 days after infection, some neoactinospores were found in the water containing a single worm. These neoactinospores were identical to those released from *B. sowerbyi*.

Histology

The first developing stages were found in the gut epithelium of a *T. tubifex* 8 days after infection. By the day 15, these had grown in number and round-shaped pansporocysts with a dark cytoplasm were seen scattered in the intestinal epithelium of the *T. tubifex* (Fig. 1). Twenty-three days after infection, a relatively heavy infection characterized by the presence of more advanced pansporocysts was seen in the hindgut of a *T. tubifex* (Fig. 2). These stages were larger and round in shape, and seemed to have an intracellular location (Fig. 2, insert). Mature pansporocysts containing spores were found only in *B. sowerbyi*. These were located in the midgut. Among the large number of spores filling the epithelium, some young pansporocysts were still detectable in the gut. At that stage, pansporocysts showed an oval or round shape, and each contained irregular-shaped sporoblast cells. In more-developed pansporocysts, the spore body with secondary cells, caudal processes and polar capsules was clearly seen. Histological preparations made from *B. sowerbyi* at day 95 after infection revealed that actinosporean spores were released from the epithelium into the gut lumen (Fig. 3). In semithin sections, it was clearly seen that pansporocysts with mature spores were located exclusively in the gut epithelium (Fig. 4). Each pansporocyst contained eight spores (Fig. 5), and in the sporoblasts of the latter, several secondary cells and the polar capsules were detectable. Even in that advanced stage of development, some young pansporocysts were commonly found with mature stages (Fig. 5).

Description of neoactinospores

The description was based on 50 neoactinospores released from *B. sowerbyi* specimens. The spore (spore body with the caudal processes) is elliptical in side view and triangular in apical view (Figs 6–8).

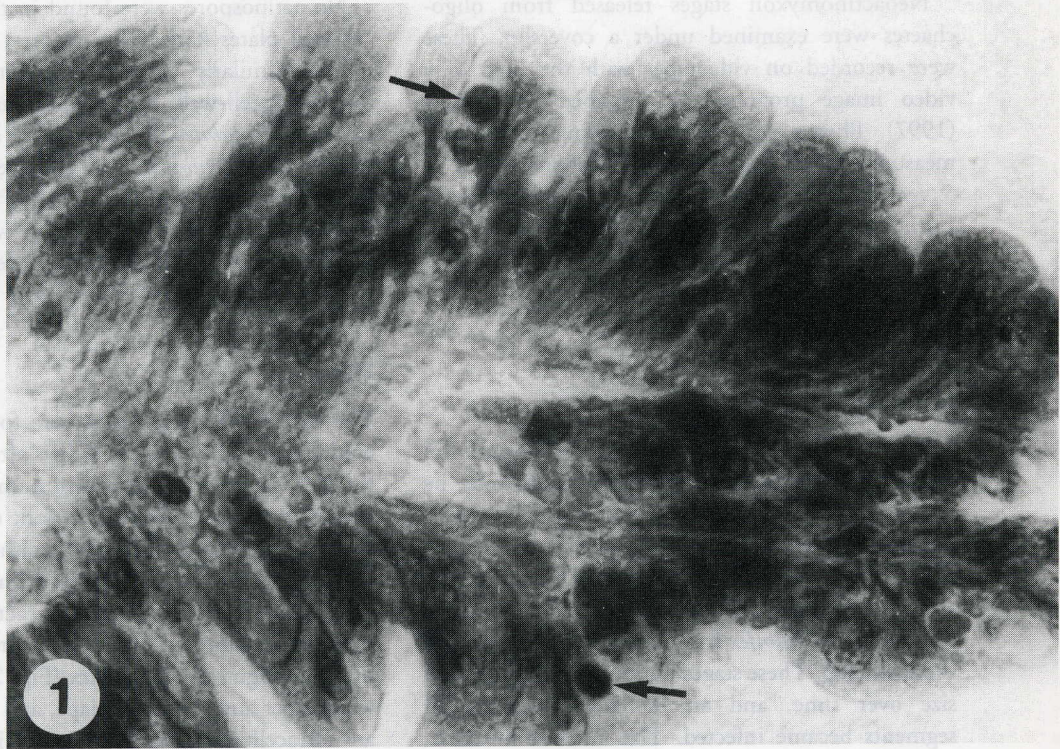


Figure 1 A lobe of the intestinal wall of *Tubifex tubifex* 15 days after infection with homogenized common carp kidneys containing *Sphaerospora renicola* spores. Young pansporocysts (arrows) are located inside the epithelium (H & E, × 1000)

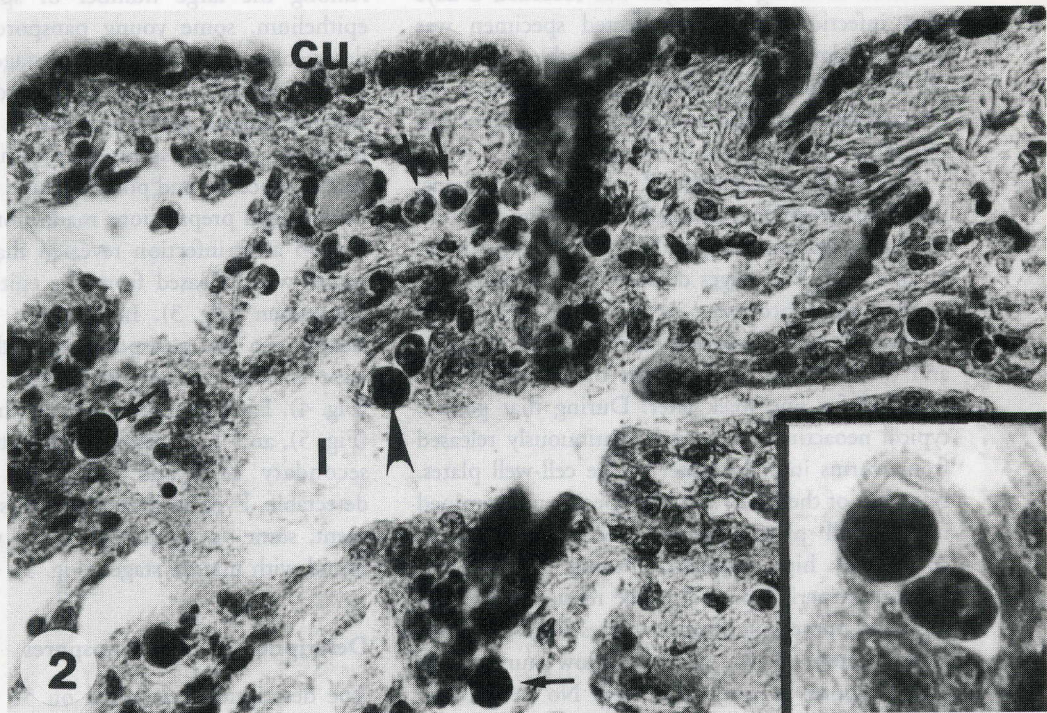


Figure 2 Cross-section of a *Tubifex tubifex* 23 days after infection. Numerous young pansporocysts (arrows) of different sizes can be seen inside the intestinal epithelium: (I) intestinal lumen; (cu) cuticle of the worm (H & E, × 400). Insert (enlargement of the part of the main figure which is indicated with an arrowhead): Pansporocysts are apparently located intracellularly (H & E, × 1000).

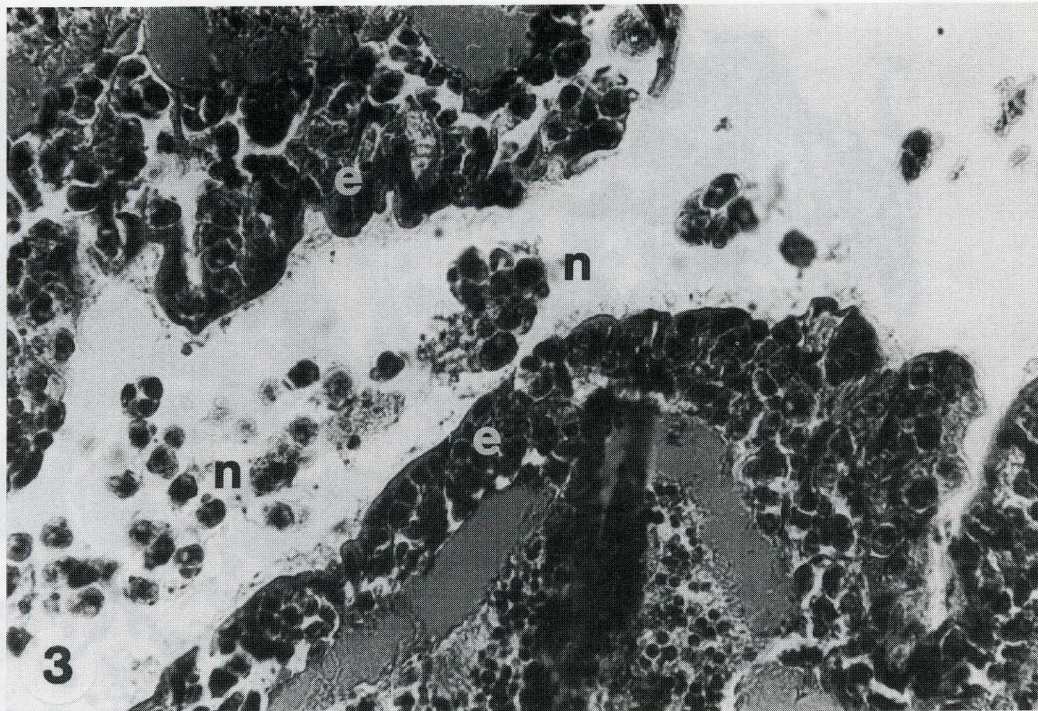


Figure 3 Intestine of a *Branchiura sowerbyi* 95 days after infection. The epithelium (e) is heavily infected with pansporocysts containing mature spores. Free neoactinospores (n) released from the epithelium are seen in the intestinal lumen (H & E, $\times 400$).

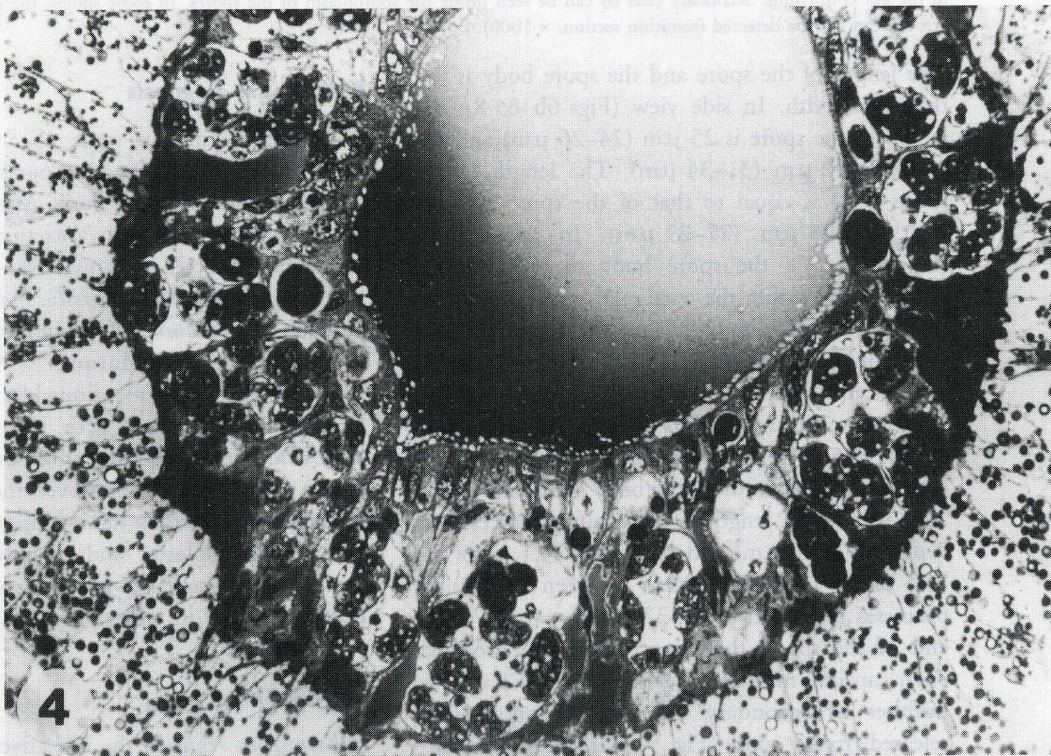


Figure 4 Intestine of a *Branchiura sowerbyi* 95 days after infection. Pansporocysts, containing eight neoactinospores each, are located in the intestinal wall (semithin section, $\times 250$).

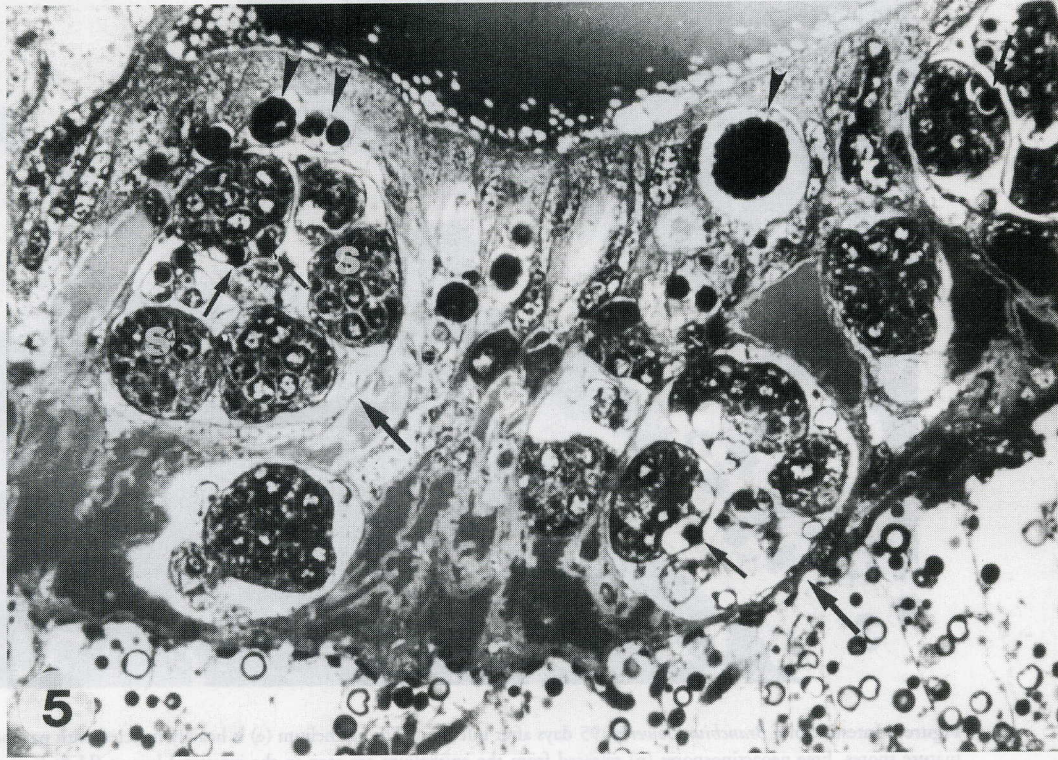


Figure 5 Advanced stages of pansporocysts (large arrows) containing mature actinospores and some young pansporocysts (arrowheads) in the gut epithelium. Secondary cells (s) can be seen inside the sporoplasm of the spores. In some spores, the polar capsules (small arrows) can also be detected (semithin section, $\times 1000$).

The length of the spore and the spore body is less than the width. In side view (Figs 6b & 8), the length of the spore is $25\ \mu\text{m}$ ($24\text{--}26\ \mu\text{m}$) and the width is $32\ \mu\text{m}$ ($31\text{--}34\ \mu\text{m}$). The length of the spore body is equal to that of the spore and the width is $28\ \mu\text{m}$ ($27\text{--}29\ \mu\text{m}$). In apical view (Figs 6a & 7), the spore body shows a typical trefoil shape within the triangular spore formed by the spore body and the caudal processes. An interlobular retraction is found in the centre of each lobule. The width of the spore body (according to the measuring points proposed by Lom *et al.* (1997a) from the middle of the lobe to the opposite interlobular part of the spore body is $22\ \mu\text{m}$ ($20.3\text{--}24.0\ \mu\text{m}$). The length of the caudal processes is $9\ \mu\text{m}$ ($8.0\text{--}9.9\ \mu\text{m}$) and the width $15.1\ \mu\text{m}$ ($15\text{--}15.5\ \mu\text{m}$). The largest span between the caudal processes is $37\ \mu\text{m}$ ($36.7\text{--}37.9\ \mu\text{m}$). At the apical end of the spore, there are three small drop-like polar capsules measuring about $2.5 \times 1.5\ \mu\text{m}$. The number of secondary cells in the sporoplasm released from a spore (Fig. 9) was counted as 16.

Differential diagnosis

The neoactinomyxon stage of *S. renicola* differs from other known neoactinospores in the shape of the spore and the spore body. Most of the known neoactinospores, such as *Neoactinomyxon globosum* (Granata), collected by Janiszewska (1955) from the gut epithelium of *Limnodrilus udekemianus* (Claparede), *N. globosum*, *N. minutum* and *N. eiseniellae*, obtained by Marques (1984), and the *Neoactinomyxon* sp., mentioned by Yokoyama *et al.* (1993) in connection with the transmission of *Hoferellus carassii* of goldfish through *B. sowerbyi*, have a globular shape. However, the neoactinomyxon stage of *S. renicola* has a triangular shape and a trifoliate sporoplasm, and resembles actinospores (type 1 and 4) collected by El-Mansy *et al.* (1998b) during a survey in a Hungarian fish farm.

Discussion

Sphaerospora renicola, the causative agent of swim-bladder disease in European carp farms, is one of the best known myxosporeans. After the pioneering

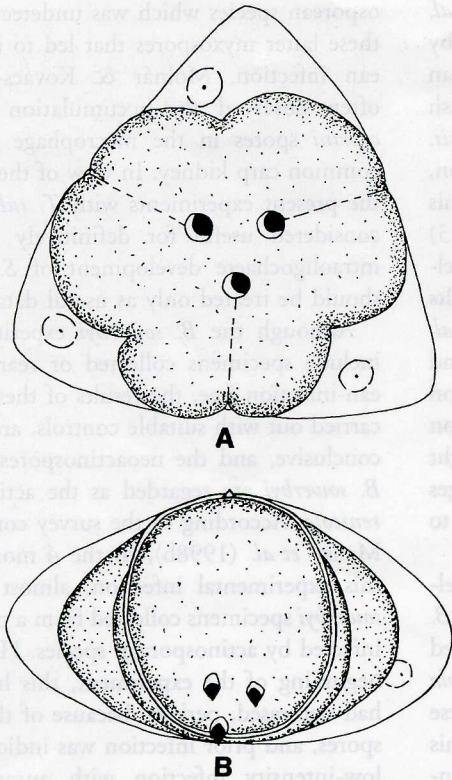


Figure 6 Schematic representation of the *Sphaerospora renicola* neoactinospore: (a) apical view; and (b) side view (bar = 10 µm).

works of Wolf & Markiw (1984), El-Matbouli & Hoffmann (1989, 1993) and Ruidisch *et al.* (1991), it would be expected that this myxosporean followed the same pattern of development as other previously studied myxosporeans, and that it developed through alternate tubificid hosts. Gros-

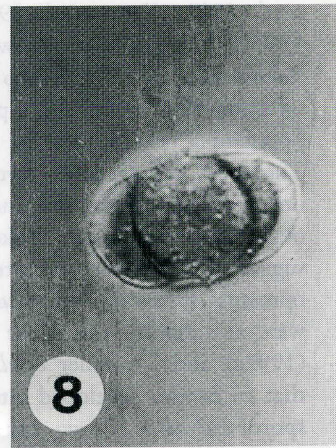


Figure 8 Side view of the released neoactinospore of *Sphaerospora renicola* (× 1200).

sheider & Körting (1993) first accomplished an artificial infection in specific pathogen-free common carp fingerlings. The above authors used filtered pond-water for infection and concluded that the infective stage would be an actinosporean able to pass through a 20-µm screen. McGeorge, Sommerville & Wootton (1997), who surveyed the occurrence of actinospores in a fish farm where *Sphaerospora truttae* infection was common, speculated that an aurantiactinomyxon might be the actinospore of *S. truttae*. Only a limited number of successful experiments have been conducted with oligochaetes so far. Most concerned *Myxobolus* spp., which developed into triactinomyxon, hexactinomyxon and raabeia stages (Wolf & Markiw 1984; El-Matbouli & Hoffmann 1989, 1993; Ruidisch

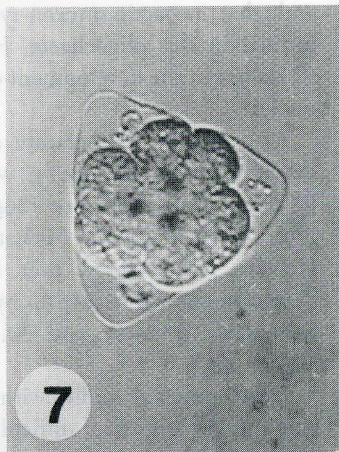


Figure 7 Apical view of the released neoactinospore of *Sphaerospora renicola* (× 1200).

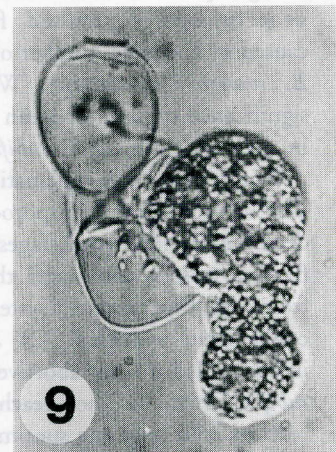


Figure 9 Sporoplasm of the neoactinospore of *Sphaerospora renicola* released from the opened spore (× 1200).

et al. 1991; Kent *et al.* 1993; Yokoyama *et al.* 1995). Neoactinospores were found only by Yokoyama *et al.* (1993), who studied actinosporean infection of *B. sowerbyi* in a pond-cultured goldfish population heavily infected by *Hofereillus carassii*. The above authors found two aurantiactinomyxon, one neoactinomyxon and one raabeia stage in this oligochaete. Although Yokoyama *et al.* (1993) suggested that neoactinospores could be the developmental forms of *Hofereillus carassii*, their results were at variance with those of El-Matbouli *et al.* (1992a) and Trouillier *et al.* (1996), who found that *H. carassii* developed into aurantiactinomyxon spores in *Nais* sp. Given that *Sphaerospora* infection is rather common in goldfish populations, it might be that one or both of the neoactinomyxon stages found by the Japanese authors might belong to *Sphaerospora* spp.

In the present experiments, actinosporean development was recorded in both *T. tubifex* and *B. sowerbyi* after infection by the addition of squashed kidney of common carp fry containing *S. renicola* myxospores. This suggests that one or both of these oligochaetes can act as an alternate host for this species. Unfortunately, difficulties were encountered in both cases. *Tubifex tubifex* was an ideal experimental organism since a large number of uninfected specimens were available. The presence of actinosporean developmental stages in this oligochaete as early as day 8 after infection and the absence of infected specimens from the controls indicates that the infection started from myxospores from carp kidney. On the other hand, neoactinospores were only released in very low numbers from a single specimen. It cannot be excluded that these neoactinospores resulted from contamination caused by the large number of spores released from *B. sowerbyi* specimens. When evaluating the significance of actinosporean developmental stages in the epithelium of *T. tubifex* from days 8 to 29 post-infection, three explanations seem possible: (1) The actinosporean pansporocysts found were indeed the developmental stages of *S. renicola*, but the fixation process eliminated the infected specimens from the experimental system before the spores could have appeared. (2) *Sphaerospora renicola* infection led to an abortive development in *T. tubifex* which did not reach spore formation or reached it in only one specimen. (3) The common carp kidneys used for experimental infection were infected not only with *S. renicola* spores, but also, at a lower level, with myxospores of another myx-

osporean species which was undetected, and it was these latter myxospores that led to the actinosporean infection. Molnár & Kovács-Gayer (1985) often observed the accumulation of *Myxobolus cyprini* spores in the macrophage centres of the common carp kidney. In view of these possibilities, the present experiments with *T. tubifex* cannot be considered useful for definitively describing the intraoligochaete development of *S. renicola*, and should be treated only as useful data.

Although the *B. sowerbyi* experiments did not include specimens collected or reared actinosporean-infection free, the results of these experiments, carried out with suitable controls, are considered as conclusive, and the neoactinospores released from *B. sowerbyi* are regarded as the actinospores of *S. renicola*. According to the survey conducted by El-Mansy *et al.* (1998b), in the 4 months preceding this experimental infection, almost all of the *B. sowerbyi* specimens collected from a pond farm were infected by actinosporean species. However, by the beginning of the experiment, this high prevalence had decreased, perhaps because of the excretion of spores, and prior infection was indicated only by a low-intensity infection with aurantiactinospores and raabeia spores in three experimental and two control worms.

The 37% prevalence, and especially the extremely intensive infection with neoactinospores in the infected group and the absence of such infection from the controls, unambiguously prove the successful infection and intraoligochaete development of *S. renicola* in *B. sowerbyi*.

From the present experiments, it is concluded that *B. sowerbyi* is an alternate host for *S. renicola*, and that neoactinomyxon-type actinospores are formed in this oligochaete. However, the role of *T. tubifex* in the development of *S. renicola* remains unclear.

At a median temperature of 20 °C, the entire development in *B. sowerbyi* was completed within 98 days. These data are roughly consistent with those of El-Matbouli, Fischer-Scherl & Hoffman (1992b), who found that the intraoligochaete development of triactinomyxon stages of *M. cerebralis*, *M. cotti* and *M. carassii* took 80–120 days.

Developmental studies with coelozoic and histozoic myxosporeans are difficult. Until the developmental cycle can definitely be elucidated by experiments using spores collected from a single, relatively large myxosporean plasmodium, samples

of species developing intercellularly in small pseudoplasmodia or in coelozoic locations can easily be contaminated by disseminated spores of other myxosporeans. The *S. renicola*-infected kidneys of common carp very often contain some *Myxobolus*, *Hoferellus* and *Thelohanellus* spores. In the present experiments, these difficulties were overcome by the use of adequate controls.

These experiments and other trials conducted on the extrapiscine life cycle of myxosporeans seem to support the view that all myxosporeans consistently develop with two alternate hosts. Some observations, like those of Odening *et al.* (1989), seem to contradict this notion. By feeding spore-containing kidneys and placing recipient carp into the water of the infected specimens, the above authors successfully transmitted *S. renicola* infection to parasite-free common carp. However, in the opinion of the present authors, these experiments do not prove a direct development. By feeding the kidneys or decaying tissues of infected common carp, intrapiscine C- and K-stages can also be transmitted to the recipient carp, and infection may result from these presporogonic intrapiscine stages. Similar experiments were carried out by Diamant (1997), who apparently successfully performed a fish-to-fish transmission of the marine myxosporean *Myxidium leei*. However, the latter author failed to define whether infection resulted from myxospores ingested with the food or was caused by the extrasporogonic intrapiscine stages latently present in pieces of organs from infected fish that died. Infection with non-sporogonic stages is well known in parasitic infections of mammals; the apicomplexan *Toxoplasma gondii* infects various mammals and humans via vegetative developmental stages, and an infection through oocysts shed by felid final hosts is accomplished less frequently (Hutchinson, Dunachie, Siim & Work 1969).

Preliminary trials to infect common carp using the neoactinospores from experimentally infected *B. sowerbyi* produced inconclusive results. Thus, the development of *S. renicola* can only be inferred from field observations made in carp farms. Thus, it appears that intrapiscine development starts with the infection of carp with neoactinospores. After the ingestion of these spores, extrasporogonic stages develop first in the endothelial cells of capillaries (Voronin & Chernysheva 1993), and then in the blood (Csaba 1976) and swimbladder (Kovács-Gayer, Csaba, Békési, Bucsek, Szokolczai & Molnár 1982; Körting 1982). This sporogonic

development ends in the formation of *S. renicola* myxospores in the renal tubules. An intraoligochaete development starts when the alternate host becomes infected with myxospores of *S. renicola*.

Acknowledgments

The authors wish to thank the National Research Foundation of Hungary (OTKA), contract nos T 20044 and T 019911, and the Balaton Secretariat of the Prime Minister's Office for the financial support for this work. The authors would also like to thank Zsuzsa Kis and Emese Papp for their technical assistance.

References

- Bartholomew J.L., Whipple M.J., Stevens D.G. & Fryer J.L. (1997) The life cycle of *Ceratomyxa shasta*, a myxosporean parasite of salmonids requires a freshwater polychaete as an alternate host. *Journal of Parasitology* **83**, 859–868.
- Benajiba M.H. & Marques A. (1993) The alternative of actinomyxidian and myxosporidian sporul forms in the development of *Myxidium giardi* (parasite of *Anguilla anguilla*) through oligochaetes. *Bulletin of the European Association of Fish Pathologists* **13**, 100–103.
- Brinkhurst R.O. (1963) A guide for the identification of British aquatic Oligochaeta. *Freshwater Biology Association Scientific Publication* **22**, 1–55.
- Csaba G. (1976) An unidentified extracellular sporozoan parasite from the blood of the carp. *Parasitologia Hungarica* **9**, 21–24.
- Csaba G., Kovács-Gayer É., Békési L., Bucsek M., Szokolczai J. & Molnár K. (1984) Studies into the possible protozoan aetiology of swimbladder inflammation in the carp fry. *Journal of Fish Diseases* **7**, 235–239.
- Diamant A. (1997) Fish-to-fish transmission of a marine myxosporean. *Diseases of Aquatic Organisms* **30**, 99–105.
- El-Mansy A. & Molnár K. (1997a) Extrapiscine development of *Myxobolus drjagini* Akhmerow, 1954 (Myxosporidia: Myxobolidae) in oligochaete alternate hosts. *Acta Veterinaria Hungarica* **45**, 427–438.
- El-Mansy A. & Molnár K. (1997b) Development of *Myxobolus hungaricus* (Myxosporidia: Myxobolidae) in oligochaete alternate hosts. *Diseases of Aquatic Organisms* **31**, 227–232.
- El-Mansy A., Molnár K. & Székely Cs. (1998a) Development of *Myxobolus portucalensis* (Myxosporidia: Myxobolidae) in the oligochaete *Tubifex tubifex* (Müller). *Systematic Parasitology* **41**, 95–103.
- El-Mansy A. & Székely Cs. & Molnár K. (1998b) Studies on the occurrence of actinosporean stages of fish myxosporeans in a fish farm of Hungary, with the description of triactinomyxon, raabeia, aurantiactinomyxon and neoactinomyxon types. *Acta Veterinaria Hungarica* **46**, 259–284.
- El-Marboui M., Fischer-Scherl T. & Hoffmann R.W. (1992a) Transmission of *Hoferellus carassi* Achmerow, 1960 to

- goldfish *Carassius auratus* via an aquatic oligochaete. *Bulletin of the European Association of Fish Pathologists* **12**, 54–56.
- El-Matbouli M., Fischer-Scherl T. & Hoffmann R.W. (1992b) Present knowledge on the life cycle, taxonomy, pathology, and therapy of some *Myxosporea* spp. important for freshwater fish. *Annual Review of Fish Diseases* **3**, 367–402.
- El-Matbouli M. & Hoffmann R.W. (1989) Experimental transmission of two *Myxobolus* spp. developing bisporogeny via tubificid worms. *Parasitology Research* **75**, 461–464.
- El-Matbouli M. & Hoffmann R.W. (1993) *Myxobolus carassii* Klokaceva, 1914 also requires an aquatic oligochaete, *B. sowerbyi* as an intermediate host in its life cycle. *Bulletin of the European Association of Fish Pathologists* **13**, 189–192.
- Grossheider G. & Körting W. (1992) First evidence that *Hoferellus cyprini* (Doflein, 1898) is transmitted by *Nais* sp. *Bulletin of the European Association of Fish Pathologists* **12**, 17–20.
- Grossheider G. & Körting W. (1993) Experimental transmission of *Sphaerospora renicola* to common carp *Cyprinus carpio* fry. *Diseases of Aquatic Organisms* **16**, 91–95.
- Hutchinson W.M., Dunachie F., Siim J. & Work K. (1969) Life cycle of *Toxoplasma gondii*. *British Medical Journal* **4**, 806.
- Janiszewska J. (1955) Actinomyxidias: morphology, ecology, history of investigation, systematics, development. *Acta Parasitologica Polonica* **2**, 405–437.
- Janiszewska J. (1957) Actinomyxidias. II. New systematics, sexual cycle, description of new genera and species. *Zoologia Poloniae* **8**, 3–34.
- Kent M.L., Whitaker D.J. & Margolis L. (1993) Transmission of *Myxobolus arcticus* Pugachev and Khokhlov, 1979, a myxosporean parasite of Pacific salmon, via a triactinomyxon from the aquatic oligochaete *Stylodrilus heringianus* (Lumbriculidae). *Canadian Journal of Zoology* **71**, 1207–1211.
- Körting W. (1982) Protozoan parasites associated with swim-bladder inflammation (SBI) in young carp. *Bulletin of the European Association of Fish Pathologists* **2**, 25–28.
- Kovács-Gayer É., Csaba Gy., Békési L., Bucsek M., Szokolczai J. & Molnár K. (1982) Studies on the protozoan aetiology of swimbladder inflammation in common carp fry. *Bulletin of the European Association of Fish Pathologists* **2**, 22–24.
- Lom J., Dyková I. & Pavlasková M. (1983) 'Unidentified' mobile protozoans from the blood of carp and some unsolved problems of myxosporean life cycles. *Journal of Protozoology* **30**, 497–508.
- Lom J., McGeorge J., Feist S.W., Morris D. & Adams A. (1997a) Guidelines for the uniform characterisation of the actinosporean stages of parasites of the phylum Myxozoa. *Diseases of Aquatic Organisms* **30**, 1–9.
- Lom J., Yokoyama H. & Dyková I. (1997b) Comparative ultrastructure of *Neoactinomyxon* and *Raabeia*, actinosporean stages of myxozoan life cycle. *Archiv für Protistenkunde* **148**, 173–189.
- Marques A. (1984) *Contribution a la connaissance des Actinomyxidies: ultrastructure, cycle biologique, systematique*. D.Sc. Thesis, Université des Sciences et Techniques du Languedoc, Montpellier.
- McGeorge J., Sommerville C. & Wootten R. (1997) Studies of actinosporean myxozoan stages parasitic in oligochaetes from the sediments of a hatchery where Atlantic salmon harbour *Sphaerospora truttae* infection. *Diseases of Aquatic Organisms* **30**, 107–119.
- Molnár K. (1980) Renal sphaerosporosis in the common carp, *Cyprinus carpio* L. *Journal of Fish Diseases* **3**, 11–19.
- Molnár K. (1988a) Further evidence that C-blood protozoa of the common carp are stages of *Sphaerospora renicola* Dykova et Lom 1982. *Bulletin of the European Association of Fish Pathologists* **8**, 3–4.
- Molnár K. (1988b) Presporogonic development of *Sphaerospora renicola* Dykova & Lom 1982 in the swimbladder of the common carp, *Cyprinus carpio* L. *Journal of Fish Diseases* **11**, 489–497.
- Molnár K. & Kovács-Gayer É. (1985) The pathogenicity and development within the host fish of *Myxobolus cyprini* Doflein, 1898. *Parasitology* **90**, 549–555.
- Odening K., Walter G. & Bockhardt I. (1989) Zum Infektionsgeschehen bei *Sphaerospora renicola* (Myxosporidia). *Angewandte Parasitologie* **30**, 131–140. (In German.)
- Ruidisch S., El-Matbouli M. & Hoffmann R.W. (1991) The role of tubificid worms as an intermediate host in the life cycle of *Myxobolus pavlovskii* Achmerov, 1954. *Parasitology Research* **77**, 663–667.
- Styer E.L., Harrison L.R. & Burtle G.J. (1991) Experimental production of proliferative gill disease in channel catfish exposed to a myxozoan-infected oligochaete, *Dero digitata*. *Journal of Aquatic Animal Health* **3**, 288–291.
- Székely Cs. (1997) Possible applications of video technology and digital image processing in fish parasitology: morphological examination of the groups Apicomplexa and Myxosporea-Actinosporea by video technology. *Bulletin of the European Association of Fish Pathologists* **17**, 81–82.
- Trouillier A., El-Matbouli M. & Hoffmann R.W. (1996) A new look at the life cycle of *Hoferellus carassii* in goldfish (*Carassius auratus*) and its relation to kidney enlargement disease (KED). *Folia Parasitologica* **43**, 173–187.
- Uspenskaya A.V. (1995) Alternation of actinosporean and myxosporean phases in the life cycle of *Zschokkella nova* (Myxozoa). *Journal of Eukaryotic Microbiology* **42**, 665–668.
- Voronin V.N. & Chernysheva N.B. (1993) An intracellular gill parasite as the possible causative agent of mortality during swim-bladder inflammation in common carp, *Cyprinus carpio* L. *Journal of Fish Diseases* **16**, 609–611.
- Wolf K. & Markiw M.E. (1984) Biology contravenes taxonomy in the Myxozoa: new discoveries show alternation of invertebrate and vertebrate hosts. *Science* **225**, 1449–1452.
- Yokoyama H. (1997) Transmission of *Thelohanellus hovorkai* Achmerov, 1960 (Myxosporea: Myxozoa) to common carp *Cyprinus carpio* through the alternate oligochaete host. *Systematic Parasitology* **36**, 79–84.
- Yokoyama H., Ogawa K. & Wakabayashi H. (1991) A new collection method of actinosporeans – a probable infective stage of myxosporeans to fish – from tubificid and experimental infection of goldfish with actinosporean, *Raabeia* sp. *Fish Pathology* **26**, 133–138.
- Yokoyama H., Ogawa K. & Wakabayashi H. (1993) Involvement of *B. sowerbyi* (Oligochaeta: annelida) in the transmission of *Hoferellus carassii* (Myxosporea: Myxozoa),

the causative agent of kidney enlargement disease (KED) of goldfish *Carassius auratus*. *Fish Pathology* **23**, 135–139.

Yokoyama H., Ogawa K. & Wakabayashi H. (1995) *Myxobolus cultus* n. sp. (Myxosporea: Myxobolidae) in goldfish *Carassius*

auratus transformed from the actinosporean stage in the oligochaete *B. sowerbyi*. *Bulletin of the European Association of Fish Pathologists* **81**, 446–451.