

## Development of *Thelohanellus hovorkai* and *Thelohanellus nikolskii* (Myxosporaea: Myxozoa) in Oligochaete Alternate Hosts

Csaba Székely<sup>1,\*</sup>, Amina El-Mansy<sup>2</sup>, Kálmán Molnár<sup>1</sup> and Ferenc Baska<sup>1</sup>

<sup>1</sup>Veterinary Medical Research Institute, Hungarian Academy of Sciences, H-1581 Budapest, P.O. Box 18, Hungary

<sup>2</sup>National Institute of Oceanography and Fisheries, Cairo, Egypt

(Received March 23, 1998)

The development of *Thelohanellus hovorkai*, a myxosporean parasite of the connective tissues, and *Thelohanellus nikolskii*, a fin and scale parasite of common carp (*Cyprinus carpio*) was studied in experimentally infected oligochaetes *Branchiura sowerbyi* and *Tubifex tubifex*, respectively. After infection with mature spores of *T. hovorkai*, the development of actinosporean stages was first observed light microscopically in the gut of *Branchiura sowerbyi* 93 days after infection. Free actinospores of *T. hovorkai* were found in the lumen of the oligochaete's gut 101 days after infection. They were floating in water and showed a typical aurantiactinomyxon form. At 18–22°C, aurantiactinomyxon spores of *T. hovorkai* emerged from the worms 104 days after infection. The development of *T. nikolskii* was examined in *Tubifex tubifex*, from which aurantiactinomyxon spores were released 60 days after infection at 22–24°C. The diameter of spore body was 18.6 µm and the length of caudal processes 29 µm for *T. hovorkai*, while 21.1 µm and 13.4 µm for *T. nikolskii*, respectively. The prevalence of aurantiactinomyxon infection in *B. sowerbyi* for *T. hovorkai* proved to be 16.7%, while in *T. tubifex* for *T. nikolskii* it was 12.5%.

**Key words:** *Thelohanellus hovorkai*, *Thelohanellus nikolskii*, Myxozoa, aurantiactinomyxon, alternate host, *Branchiura sowerbyi*, *Tubifex tubifex*

Since Wolf and Markiw (1984) published their essential paper on the life cycle of *Myxobolus cerebralis*, several other papers supporting their results have appeared. These papers (El-Matbouli *et al.*, 1992; Kent *et al.*, 1993; Yokoyama *et al.*, 1993; Uspenskaya, 1995) revealed that in each case various Oligochaeta spp. acted as alternate hosts in the development of various myxosporean species.

To date, 7 *Thelohanellus* species have been described from the common carp. All of them were recorded from *Cyprinus carpio haematopterus* in the Far-East. While studying parasites of the Amur River fishes, Akhmerov (1955, 1960) identified 5 host- and organ-specific *Thelohanellus* species (*T. acuminatus*, *T. amurensis*, *T. dogieli*, *T. nikolskii* and *T. hovorkai*) from the gills, liver, skin, fins and mesentery of the amur wild carp, respectively. The number of *Thelohanellus* species increased when Hoshina and Hosoda (1957), not knowing Akhmerov's work (1955), described *T. nikolskii* under the name *T. cyprini* from the fins. Among these

species Shulman (1962) regarded only *T. dogieli* to be valid, and considered *T. nikolskii*, *T. amurensis*, *T. cyprini* and *T. hovorkai* to be synonymous with *T. dogieli*, and *T. acuminatus* to be synonymous with *T. fuhrmanni* (Auerbach, 1909). The occurrence of a *Thelohanellus* species in Hungary was reported by Jeney (1979) who identified the parasites found on the fins of the common carp as *T. dogieli*, and believed that it was introduced to Europe by Far-Eastern carps. Molnár and Kovács-Gayer (1981–82), who revitalized Akhmerov's classification found two introduced species infecting fingerlings of the European common carp, namely *T. nikolskii*, a parasite of the fin and *T. hovorkai*, a parasite of the mesenteries and conjunctive tissues. Moshu and Molnár (1997) revealed that *T. nikolskii* can infect also older specimens of the common carp. In older fish, however, the plasmodia are located in the tips of the scales.

The pathology of *T. nikolskii* was studied by Molnár (1982) who reported large plasmodia growing on the finrays, destroying the structure of the cartilageous elements and breaking down the fins. The pathology

\* E-mail: szekely@novell.vmri.hu

of *T. hovorkai* was described by Yokoyama *et al.* (1998), who found severe haemorrhages on the body surface of the affected common carp and designated the disease as "haemorrhagic thelohanellosis".

The intraoligochaete development of *T. hovorkai* has already been demonstrated by Yokoyama (1997) who found aurantiactinomyxon stages in experimentally infected *Branchiura sowerbyi*. A comparative ultrastructural study on aurantiactinomyxon and raabeia stages has been carried out by Lom *et al.* (1997a).

During a research on the intraoligochaete development of myxosporeans the development of some *Myxobolus*, *Thelohanellus* and *Sphaerospora* species was studied experimentally under laboratory conditions. Within this program, successful experiments have been performed and some of their results have been described (El-Mansy and Molnár, 1997, 1998; El-Mansy *et al.*, 1998a) or prepared for publication. The present paper reports on two experiments in which the oligochaete *Branchiura sowerbyi* was infected with myxospores of *T. hovorkai*, and *Tubifex tubifex* was infected with myxospores of *T. nikolskii*, and in these worms actinosporean stages belonging to the aurantiactinomyxon-type developed.

## Materials and methods

### Source of spores and oligochaetes

Spores of *T. hovorkai* were obtained from a single large plasmodium located in the gill arch of a one-year-old common carp *Cyprinus carpio*, from a Hungarian fish farm, while spores of *T. nikolskii* were collected from several small plasmodia infecting the scales of four-year-old common carp from Kis-Balaton Water Reservoir.

*Branchiura sowerbyi* (Beddard) specimens used in the experiments were collected from the mud of a fish pond, selected from other oligochaetes, cleaned and placed in 2-ml wells, and examined for the presence or absence of actinosporean infection (Yokoyama *et al.*, 1991). The remaining *Branchiura* specimens were placed into an aerated aquarium and used in experiments when necessary. Only those *Branchiura* specimens were used for the experiments which had been kept in laboratory culture for at least 6 months.

Specimens of *Tubifex tubifex* and *Limnodrilus hoffmeisteri* were collected from a muddy pool near the top of a hill where no fishes live. They were transferred into sterilized mud and propagated in the laboratory in aerated aquaria as parasite-free stocks. Oligochaetes were identified according to Brinkurst (1963).

All the worms were fed on some drops of granulated fish food, and pieces of chicken feces were added to increase the organic matter content of the mud. Normal tap water was used throughout the experiments. The temperature of the room varied between 18 and 22°C for *T. hovorkai* and between 22 and 24°C for *T. nikolskii*.

### Laboratory experiment on *T. hovorkai*

Two types of dishes were used. Some of the oligochaetes were placed into small aquaria containing 5 l of water, while others were transferred into small plastic cups of 0.5 l volume. All dishes were permanently aerated, and supplied regularly with fresh water to compensate for evaporation and to refresh the water. The aquaria contained about 100 *Branchiura sowerbyi* together with approximately 900 *Tubifex tubifex* and *Limnodrilus hoffmeisteri* specimens, while the plastic cups contained 50 *Branchiura sowerbyi* with about 40 *Tubifex* and *Limnodrilus* specimens. The oligochaetes were infected by adding *T. hovorkai* spores to the dishes. An aquarium and a small cup containing the same species and number of oligochaetes from the same stock were used as controls.

The release of the actinosporean stages of *T. hovorkai* was followed by the methods described below:

(1) Twice a week some of the oligochaetes were placed carefully under a coverslip and examined under microscope at 200 × magnification for the presence of developmental stages. (2) From the third week after infection, oligochaetes of each species (*B. sowerbyi*, *T. tubifex* and *L. hoffmeisteri*) were placed into 2-ml cell well plates (Yokoyama *et al.*, 1991) 3 times a week from all the four dishes, and after a one-day incubation at room temperature they were checked for the release of actinospores under a microscope. (3) Every second day, water from the aquaria and the plastic cups was filtered through a fine mesh of 10 µm pore size. The filtrates were taken up in a small volume of water and examined for the presence of actinosporean stages. (4) For histological examination the first oligochaetes were fixed only three months after infection. Within a month interval, 14 *B. sowerbyi*, 4 *T. tubifex* and 4 *L. hoffmeisteri* specimens were fixed in Bouin's solution, embedded in paraffin wax, cut into 5 µm thick sections, and stained with haematoxylin and eosin. One *Branchiura* specimen releasing actinospores was fixed in 2% osmium tetroxide, washed several times with cacodylate buffer, dehydrated and embedded in Durcupan ACM resin. Semithin sections (0.5–1.0 µm in thickness) were cut with glass knives and stained with 0.1% methylene blue

solution.

#### Laboratory experiment on *T. nikolskii*

In this experiment only two plastic cups containing 20 *Branchiura* and approximately 50 *Tubifex* and *Limnodrilus* specimens each were used. One of the plastic cups contained oligochaetes exposed to myxospores of *T. nikolskii*, while the other cup served as control. Only the water in these cups was examined after filtration using 10 µm nylon mesh. Oligochaetes were squashed only after the first waterborne stages had been found.

Actinospores released from the oligochaetes were examined under a coverslip. They were recorded with the help of a video image program on videotapes (Szőkely, 1997). Photos and drawings were made and measurements were recorded. All measurements in the description are given as mean (range) in µm on the basis of 25 measured spores.

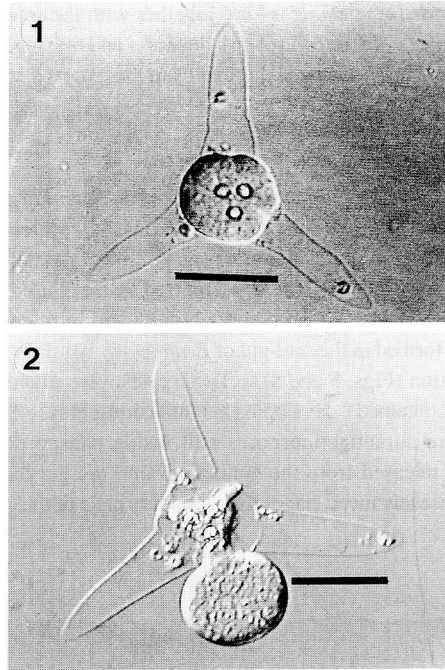
The actinosporean stages of *T. hovorkai* and *T. nikolskii* were described according to the terminology of Janiszewska (1957) as modified by Lom *et al.* (1997b).

## Results

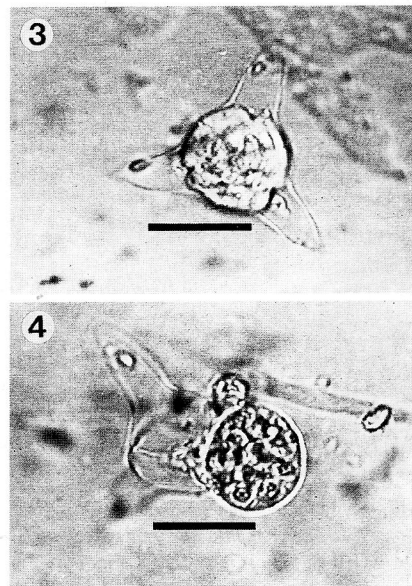
#### Light microscopy

Infection with *T. hovorkai* was found only in *B. sowerbyi*. *Tubifex* and *Limnodrilus* specimens remained uninfected. Due to their thick body and the mud-filled intestine, the developmental stages of *T. hovorkai* could not be detected externally by light microscopy. Actinospores were first released from live *B. sowerbyi* into the water 104 days after infection, and their presence in the water was recorded for about 20 days after the start of release. The released actinospores proved to be typical aurantiactinomyxon stages (Figs. 1 and 2). Eight (16.7%) of the 48 *Branchiura* specimens studied in well plates released actinospores. No actinospores were found in the 50 control *B. sowerbyi* specimens.

The development of *T. nikolskii* was detected only in *Tubifex tubifex*. Sixty days after infection a large number of aurantiactinospores were found in the water of the infected plastic cup. During a period of 3.5 weeks after the first record of actinospores, 3 (12.5%) of the 24 squashed *Tubifex tubifex* specimens randomly collected from the experimental cup proved to be infected with typical aurantiactinomyxon stages (Figs. 3 and 4). No actinospores were found in 15 *Branchiura* and 24



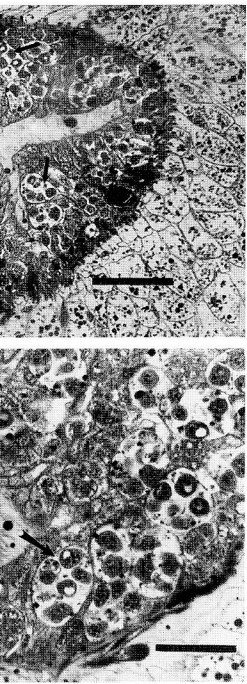
**Figs. 1–2.** Waterborne aurantiactinospore of *Thelohanellus hovorkai* floating in the water 104 days post infection. **Fig. 2.** showing discharge of sporoplasm. Digitized video image. Bar = 20 µm



**Figs. 3–4.** Waterborne aurantiactinospore of *Thelohanellus nikolskii* released into the water 124 days post infection. **Fig. 4.** showing discharge of sporoplasm. Digitized video image. Bar = 20 µm

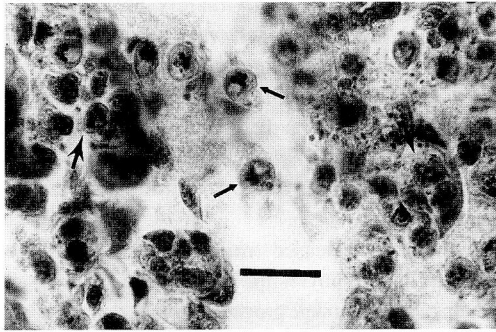
together with the infected  
at the water and the squashed  
er as in the exposed stock)

stages of *T. hovorkai* were  
ens 93 days after infection.  
t relatively young and ma-  
occurred in the gut epithe-  
s (24–48 µm in diameter)  
of *Branchiura* 101 days after  
these cysts were round and  
aurantiactinospores. Some  
still inside pansporocysts  
epithelium into the gut lumen.  
secondary cells of the spore

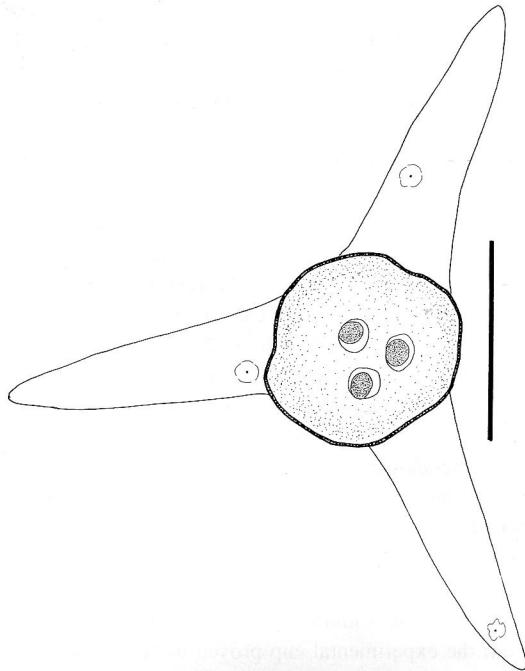


*Branchiura sowerbyi* infected  
*hovorkai* mature actinospores  
(infection). **Fig. 5:** Arrows indi-  
cating the development of  
actinospores of *T. hovorkai* develop-  
ment in the gut epithelium. Bar = 200 µm **Fig. 6:**  
High magnification of the gut epithelium.  
well-discernible polar capsules.

body and some of the caudal processes were well dis-  
cernible (Fig. 7).



**Fig. 7.** Histological section of the gut of an experimentally infected *Branchiura sowerbyi*. Large arrows indicate pansporocysts containing mature aurantiactinospores of *Thelohanellus hovorkai* in the gut epithelium. Small arrows indicate free aurantiactinospores of *T. hovorkai* released from the intestinal epithelium into the lumen. The epispore and some of the caudal processes are well discernible. Stained with haematoxylin and eosin. Bar = 60 µm



**Fig. 8.** Schematic illustration of the aurantiatinomyxon spore of *Thelohanellus hovorkai*. Bar = 20 µm.

**Table 1.** Comparison of the present studies

Myxospore	Oligochaete host	Study
<i>T. hovorkai</i> (Yokoyama, 1997)	<i>Branchiura sowerbyi</i>	(Yokoyama, 1997)
<i>T. hovorkai</i> (The present study)	<i>Branchiura sowerbyi</i>	(The present study)
<i>T. nikolskii</i> (The present study)	<i>Tubifex tubifex</i>	(The present study)

\* n.d. = not determined  
Measurements of the pres

*Description of aurantiact*

*Thelohanellus hovorkai*:  
released from *B. sowerbyi*  
proximately spherical  
moderately irregular spo-  
long, triangle-shaped cau-  
spore body (Fig. 8). Si-  
the spore body 18.6 (18-  
polar capsule 3.42 (3.4-  
The length of the caudal  
the width at the base of th  
apical view. The large-  
two caudal processes 6:  
of infective cells was 32

*Thelohanellus nikolskii*  
released from *T. tubifi*  
spherical polar capsules,  
with relatively short, tri-  
surrounding the spore.  
The diameter of the spo-  
length and width of th  
The length of the caudal  
width at the base of the s  
9.6). The largest span  
processes 40.5 (40-41),  
was 16 (Table 1).

*Differential diagnosis:*

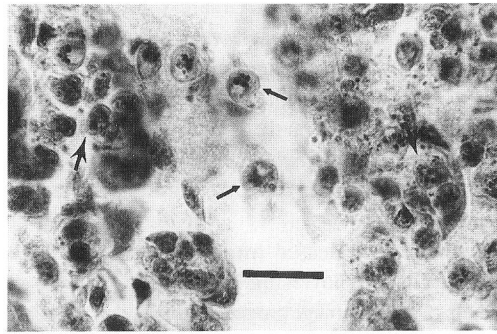
The biological and r  
actinospores, obtained  
proved to be the same a  
(1997) in his experime  
species. The aurant

*Limnodrilus* specimens kept together with the infected *T. tubifex*. In the control dish the water and the squashed oligochaetes (the same number as in the exposed stock) proved to be negative.

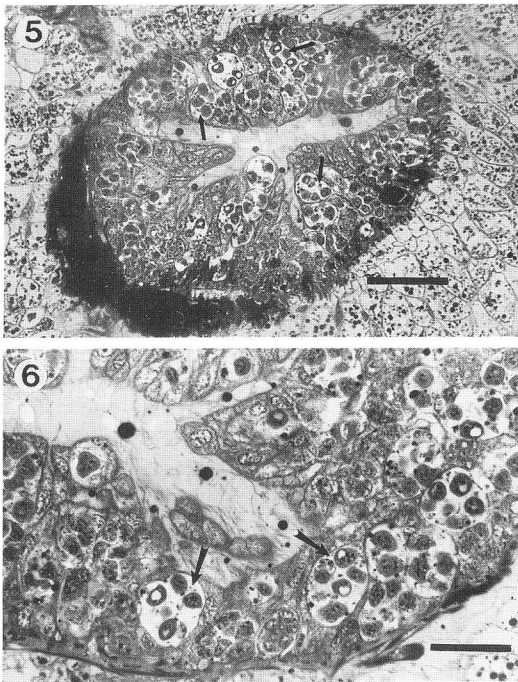
#### Histological findings

The first developmental stages of *T. hovorkai* were found in *Branchiura* specimens 93 days after infection. At that stage of development relatively young and mature pansporocysts equally occurred in the gut epithelium. Mature pansporocysts (24–48 µm in diameter) were formed in the mid-gut of *Branchiura* 101 days after infection (Figs. 5 and 6). These cysts were round and each contained 8 developing aurantiactinospores. Some mature aurantiactinospores still inside pansporocysts were released from the epithelium into the gut lumen. In these advanced stages the secondary cells of the spore

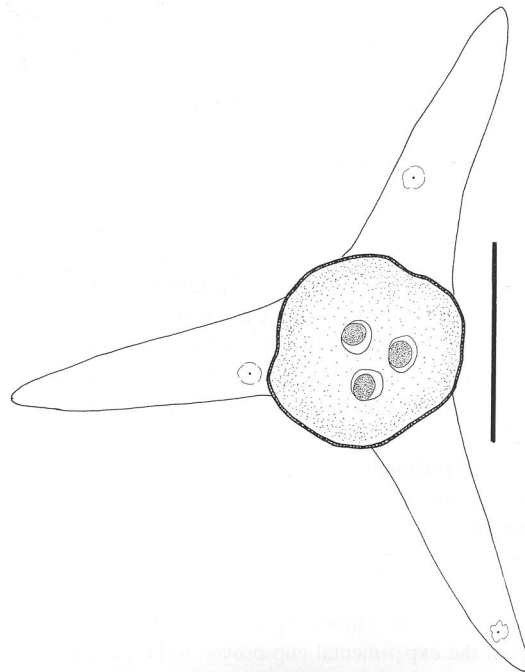
body and some of the caudal processes were well discernible (Fig. 7).



**Fig. 7.** Histological section of the gut of an experimentally infected *Branchiura sowerbyi*. Large arrows indicate pansporocysts containing mature aurantiactinospores of *Thelohanellus hovorkai* in the gut epithelium. Small arrows indicate free aurantiactinospores of *T. hovorkai* released from the intestinal epithelium into the lumen. The episore and some of the caudal processes are well discernible. Stained with haematoxylin and eosin. Bar = 60 µm



**Figs. 5–6.** Semithin section of *Branchiura sowerbyi* infected with *Thelohanellus hovorkai* mature actinospores (101 days post infection). **Fig. 5:** Arrows indicate aurantiactinospores of *T. hovorkai* developing in the gut epithelium. Bar = 200 µm **Fig. 6:** Higher magnification of the gut epithelium. Arrows indicate well-discernible polar capsules. Bar = 80 µm



**Fig. 8.** Schematic illustration of the aurantiactinomyxon spore of *Thelohanellus hovorkai*. Bar = 20 µm.

**Table 1.** Comparison of the aurantiactinospores of *Thelohanellus hovorkai* and *Thelohanellus nikolskii* of the previous and the present studies

Myxospore	Oligochaete host	Spore body diameter (range)	Caudal process length (range)	Caudal process width at base in apical view (range)	Largest span (range)	Polar capsule width (range)	Polar capsule length (range)	Number of infective cells
<i>T. hovorkai</i> (Yokoyama, 1997)	<i>Branchiura sowerbyi</i>	(18–22)	(25–33)	n.d.*	n.d.	n.d.	n.d.	32
<i>T. hovorkai</i> (The present study)	<i>Branchiura sowerbyi</i>	18.6 (18.3–18.9)	29 (28.2–29.6)	9.2 (8.1–10.2)	65.2 (65.1–65.3)	3.36 (3.3–3.4)	3.42 (3.4–3.5)	32
<i>T. nikolskii</i> (The present study)	<i>Tubifex tubifex</i>	21.1 (21–21.2)	13.4 (11.3–15.5)	9.0 (8.5–9.6)	40.5 (40–41)	2.1 (2.0–2.2)	2.1 (2.0–2.2)	16

\* n.d. = not determined

Measurements of the present study are given in  $\mu\text{m}$  on the basis of 25 spores

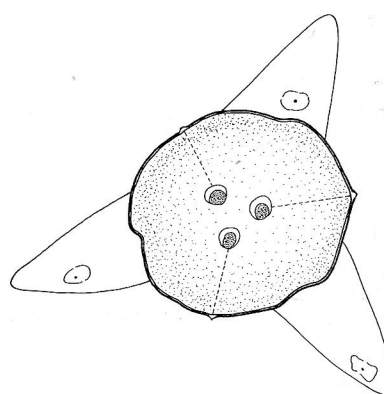
#### Description of aurantiactinospores

*Thelohanellus hovorkai*: Waterborne aurantiactinospores released from *B. sowerbyi* characterized by three approximately spherical polar capsules, globose but moderately irregular sporoplasm with three relatively long, triangle-shaped caudal processes surrounding the spore body (Fig. 8). Style absent. The diameter of the spore body 18.6 (18.3–18.9). The length of the polar capsule 3.42 (3.4–3.5), the width 3.36 (3.3–3.4). The length of the caudal processes 29 (28.2–29.6) and the width at the base of the spore body 9.2 (8.1–10.2) in apical view. The largest span between the ends of the two caudal processes 65.2 (65.1–65.3). The number of infective cells was 32 (Table 1).

*Thelohanellus nikolskii*: Waterborne aurantiactinospores released from *T. tubifex* are characterized by three spherical polar capsules, a moderately globose sporoplasm with relatively short, triangle-shaped caudal processes surrounding the spore body (Fig. 9). Style absent. The diameter of the spore body 21.1 (21–21.2). The length and width of the polar capsules 2.1 (2.0–2.2). The length of the caudal processes 13.4 (11.3–15.5), the width at the base of the spore body in apical view 9 (8.5–9.6). The largest span between the ends of the caudal processes 40.5 (40–41). The number of infective cells was 16 (Table 1).

#### Differential diagnosis:

The biological and morphological characteristics of actinospores, obtained in our *T. hovorkai* experiment, proved to be the same as those observed by Yokoyama (1997) in his experiments on the life cycle of the same species. The aurantiactinospores of *T. hovorkai*

**Fig. 9.** Schematic illustration of the aurantiactinomyxon spore of *Thelohanellus nikolskii*. Bar = 20  $\mu\text{m}$ .

differ from those of *T. nikolskii* by the smaller diameter of the spore body and the longer caudal processes. Their oligochaete alternate host is different. The aurantiactinospores of *T. hovorkai*, however, resemble those of the proliferative gill disease myxosporean which infects *Dero digitata* (Burtle *et al.*, 1991). In the latter species the length of caudal processes (29.5  $\mu\text{m}$ ) and the diameter of spore body (19.5  $\mu\text{m}$ ) are about the same as those of *T. hovorkai*; however the spores of the two aurantiactinomyxon types differ in the number of the infective secondary cells.

### Discussion

*Thelohanellus hovorkai* and *T. nikolskii* are common and specific parasites of common carp fingerlings in Hungarian pond farms (Molnár and Kovács-Gayer, 1981–1982). Both parasites were introduced to Europe from the Far East with the Amur wild carp (*Cyprinus carpio haematopterus*) at the end of the 'seventies of this century (Jeney, 1979; Molnár and Kovács-Gayer, 1981–1982). *Thelohanellus hovorkai* is a parasite of the connective tissue and occurs in all parts of the fish body, while plasmodia of *T. nikolskii* grow in large cysts in the fin rays of fingerlings (Molnár, 1982; Molnár and Kovács-Gayer, 1986). In a recent paper Moshu and Molnár (1997) have pointed out that the latter parasite commonly occurs also in carp of large body size, but in these fish the cysts develop in the tip of the collagenic plates of the scales, and spore maturation takes place in May.

Yokoyama (1997) performed successful life cycle experiments with *Thelohanellus hovorkai* for the first time, using Japanese common carp and *Branchiura sowerbyi*, and found that the actinosporean phase of development of *T. hovorkai* took place in *B. sowerbyi*. In that oligochaete aurantiactinosporean stages developed and aurantiactinospores were released into the water. Our aurantiactinospores proved to be the same as those described by the Japanese author. In a similar way, aurantiactinomyxon stages were found in the intraoligochaete development of *T. nikolskii* as well. The actinospores of the latter species, however, clearly differed in their morphology from those of *T. hovorkai*. While the actinospores of *T. hovorkai* had relatively long caudal processes, the caudal processes of *T. nikolskii* were relatively stout.

Several genera of myxosporeans seem to develop through aurantiactinospores. In addition to the three unidentified types (*A. raabeiunioris* Janiszewska, 1957, *A. trifolium* Marques, 1984, *Aurantiactinomyxon* sp. Yokoyama *et al.*, 1993), the intraoligochaete stages of the PGD organism, *Hoferellus carassii*, *H. cyprini* and *Myxidium giardi* have aurantiactinomyxon stages during their development (Burtle *et al.*, 1991; El-Matbouli *et al.*, 1992; Grossheider and Körting, 1992; Benajiba and Marques, 1993). It seems that aurantiactinospores can develop in species of several oligochaete genera. The above-listed authors reported aurantiactinomyxon stages from *Tubifex*, *Limnodrilus*, *Branchiura*, *Dero* and *Nais* spp. At present there is insufficient information to determine whether actinosporeans have a strict or a

broad host specificity toward their oligochaete alternate hosts. Although in the present experiments only single species proved to be an adequate host for *T. nikolskii* or *T. hovorkai*, respectively, on the basis of single experiment it is impossible to state that *T. hovorkai* develops only in *B. sowerbyi* or *T. nikolskii* develop only in *Tubifex tubifex*.

Up to the present we have made no attempts to infect common carp with aurantiactinospores; however, the development of *T. nikolskii* in the common carp and in *Tubifex tubifex* seems to promise an excellent future model for studying the life cycle of myxosporeans and the host-parasite relationship in the two alternate hosts. Both *Tubifex tubifex* and *Cyprinus carpio* are organisms that can easily be cultured under laboratory conditions and the formation of *T. nikolskii* plasmodia on the fish can easily be followed in experiments.

Having a good experimental model is especially important for studying the effect of temperature on the progress of development. The present experiment revealed that the intraoligochaete development of *T. hovorkai* was of different duration from that of *T. nikolskii*. While *T. hovorkai* formed actinospore after more than three months of intraoligochaete stage the release of *T. nikolskii* spores started within two months. It is assumed that differences found between the two species originate from the dissimilarities of water temperature during the experiment. While the development of *T. hovorkai* was followed at a constant temperature of 18 to 22°C, that of *T. nikolskii* was studied during the summer, when daily temperature varied between 22 and 24°C. Of the experimental oligochaetes, *Tubifex tubifex* seems to be more suitable for examination as in this transparent worm even the early developmental stages can be recognized. On the other hand due to the thick body and mud-containing gut, developmental stages could not be recognized in *Branchiura sowerbyi* even in heavy infections. Nevertheless *Tubifex* cannot be used as a substitute for *Branchiura* as the results of our experiments show that even such closely related parasites as *T. hovorkai* and *T. nikolskii* develop in two different alternate hosts. We have no explanation why actinospores of *T. hovorkai* were found only in *Branchiura* and those of *T. nikolskii* only in *Tubifex* specimens. Similarly, it is unknown why mature actinospores and young stages occurred together in the same oligochaete at the same time. Perhaps a reinfection by myxospores may have taken place in these cases.

Aurantiactinomyxon stages seem to be common in th

water of fish farms (Burtle *et al.*, 1991; McGeorge *et al.*, 1997). In a survey on the actinospores of a Hungarian fish farm (El-Mansy *et al.*, 1998b), actinospores of both of the above *Thelohanellus* species were easily detected in the filtered water of the ponds and in the oligochaetes surveyed.

According to these patterns, after infection of the common carp with aurantiactinospores an intrapiscine development takes place in the connective tissue (*T. hovorkai*) or in the fins or scales (*T. nikolskii*), while an intraoligochaete development starts when the alternate hosts become infected with myxospores of *T. hovorkai* and *T. nikolskii*, respectively.

### Acknowledgments

The authors wish to thank the Hungarian Scientific Research Fund (OTKA), contract No. T 20044 and the Balaton Secretariat of the Prime Minister's Office for supplying the funds that constituted the financial basis of the work. The authors thank Zsuzsa Kis and Emese Papp for technical assistance.

### References

- Akhmerov, A. Kh. (1955): Ways of the origin of Myxosporidia species of the genus *Thelohanellus* Kudo from Amur wild carp. *Dokl. Akad. Nauk SSSR*, **105**, 1129–1132. (in Russian).
- Akhmerov, A. Kh. (1960): Myxosporidia of fish in the basin of River Amur. In: *Rybnoe Khozyaistvo vnutrennikh vodoemov Latvviskoi SSR*, **5**, 239–308. (in Russian).
- Benajiba, M. H. and A. Marques (1993): The alternation of actinomyxidian and myxosporidian sporul forms in the development of *Myxidium giardi* (parasite of *Anguilla anguilla*) through oligochaetes. *Bull. Eur. Ass. Fish Pathol.*, **13**, 100–103.
- Brinkhurst, R. O. (1963): A guide for the identification of British aquatic Oligochaeta. Freshwater Biological Association Scientific Publication., No. 22, pp. 50.
- Burtle, G. J., L. R. Harrison and E. L. Styer (1991): Detection of triactinomyxid myxozoan in an oligochaete from ponds with proliferative gill disease in channel catfish. *J. Aquat. Anim. Health*, **3**, 281–287.
- El-Mansy, A. and K. Molnár (1997): Extrapiscine development of *Myxobolus drjagini* Achmerov, 1954 (Myxosporidia: Myxobolidae) in oligochaete alternative hosts. *Acta Vet. Hung.*, **45**, 427–438.
- El-Mansy, A. and K. Molnár (1998): Development of *Myxobolus hungaricus* Jacsó, 1940 (Myxosporidia: Myxobolidae) in oligochaete alternate hosts. *Dis. Aquat. Org.*, **31**, 227–232.
- El-Mansy, A., K. Molnár and Cs. Székely (1998a): Development of *Myxobolus portucalensis* Saraiva et Molnár, 1990 (Myxosporidia: Myxobolidae) in the oligochaete *Tubifex tubifex* (Müller). *Syst. Parasitol.*, (in press).
- El-Mansy, A., Cs. Székely and K. Molnár (1998b): Studies on the occurrence of actinosporean stages of fish myxosporidia in a fish farm of Hungary, with the description of triactinomyxon, raabeia, aurantiactinomyxon and neoactinomyxon types. *Acta Vet. Hung.*, **46**, 259–284.
- El-Matbouli, M., T. Fischer-Scherl and R. W. Hoffmann (1992): Transmission of *Hoferellus carassii* Achmerov, 1960 to goldfish *Carassius auratus* via an aquatic oligochaete. *Bull. Eur. Ass. Fish Pathol.*, **12**, 54–56.
- Grossheider, G. and W. Körting (1992): First evidence that *Hoferellus cyprini* (Doflein, 1898) is transmitted by *Nais* sp. *Bull. Eur. Ass. Fish Pathol.*, **12**, 17–20.
- Janiszewska, J. (1957): Actinomyxidia II. New systematics, sexual cycles, description of new genera and species. *Zool. Pol.*, **8**, 3–34.
- Jeney, G. (1979): The occurrence of *Thelohanellus dogieli* Achmerov, 1955 (Myxosporidia) on carp (*Cyprinus carpio*) in fish ponds in Hungary. *Parasit. Hung.*, **12**, 19–20.
- Kent, M. L., D. J. Whitaker and L. Margolis (1993): Transmission of *Myxobolus arcticus* Pugachev and Khokhlov, 1979, a myxosporidian parasite of Pacific salmon, via a triactinomyxon from the aquatic oligochaete *Stilodrilus heringianus* (Lumbriculidae). *Can. J. Zool.*, **72**, 932–937.
- Lom, J., H. Yokoyama and I. Dyková (1997a): Comparative ultrastructure of Aurantiactinomyxon and Raabeia, actinosporean stages of myxozoan life cycle. *Arch. Protistenkd.*, **148**, 173–189.
- Lom, J., J. McGeorge, S. W. Feist, D. Morris and A. Adams (1997b): Guidelines for the uniform characterisation of the actinosporean stages of parasites of the phylum Myxozoa. *Dis. Aquat. Org.*, **30**, 1–9.
- Marques, A. (1984): Contribution à la connaissance des Actinomyxidies: ultrastructure, cycle biologique, systématique. *Ph. D. Thesis*, Université des Sciences et Techniques du Languedoc, Montpellier, France.
- McGeorge, J., C. Sommerville and R. Wootten (1997): Studies of actinosporean myxozoan stages parasitic in oligochaetes from the sediments of a hatchery where Atlantic salmon harbour *Sphaerospora truttae* infection. *Dis. Aquat. Org.*, **30**, 107–119.
- Molnár, K. (1982): Biology and histopathology of *Thelohanellus nikolskii* Achmerov, 1955 (Myxosporidia, Myxozoa), a protozoan parasite of the common carp (*Cyprinus carpio*). *Z. Parasitenkd.*, **68**, 269–277.
- Molnár, K. and É. Kovács-Gayer (1981–1982): Occurrence of two species of *Thelohanellus* (Myxosporidia: Myxozoa) of Far-East origin in common carp populations of the Hungarian fish farms. *Parasit. Hung.*, **14**, 51–55.
- Molnár, K. and É. Kovács-Gayer (1986): Biology and histopathology of *Thelohanellus hovorkai* Achmerov, 1960 (Myxosporidia, Myxozoa), a protozoan parasite of the common carp (*Cyprinus carpio*). *Acta Vet. Hung.*, **34**, 67–72.
- Moshu, A. and K. Molnár (1997): *Thelohanellus* (Myxosporidia: Myxozoa) infection of the scales in the European wild carp *Cyprinus carpio carpio*. *Dis. Aquat. Org.*, **28**, 115–

123.

- Székely, Cs. (1997): Possible applications of video technology and digital image processing in fish parasitology: Morphological examination of the groups Apicomplexa and Myxosporea-Actinosporea by video technology. *Bull. Eur. Ass. Fish Pathol.*, **17**, 81–82.
- Uspenskaya, A. V. (1995): Alternation of actinosporean and myxosporean phases in the life cycle of *Zschokella nova* (Myxozoa). *J. Euk. Microbiol.*, **42**, 665–668.
- Wolf, K. and M. E. Markiw (1984): Biology contravenes taxonomy in the myxozoa: new discoveries show alternation of invertebrate and vertebrate hosts. *Science* **225**, 1449–1452.
- Yokoyama, H. (1997): Transmission of *Thelohanellus hovorkai* Achmerov, 1960 (Myxosporea: Myxozoa) to common carp *Cyprinus carpio* through the alternate oligochaete host. *Syst. Parasitol.*, **36**, 79–84.
- Yokoyama, H., K. Ogawa and H. Wakabayashi (1991): A new collection method of actinosporeans — A probable infective stage of myxosporeans to fish — from tubificid and experimental infection of goldfish with the actinosporean, *Raabeia* sp. *Fish Pathol.*, **26**, 133–138.
- Yokoyama, H., K. Ogawa and H. Wakabayashi (1993): Involvement of *Branchiura sowerbyi* (Oligochaeta: Annelida) in the transmission of *Hoferellus carassii* (Myxosporea Myxozoa), the causative agent of kidney enlargement disease (KED) of goldfish *Carassius auratus*. *Fish Pathol.* **28**, 135–139.
- Yokoyama, H., Y. S. Liyanage, A. Sugai and H. Wakabayashi (1998): Hemorrhagic thelohanellosis of color carp caused by *Thelohanellus hovorkai* (Myxozoa: Myxosporea). *Fish Pathol.*, **33**, 85–89.