

## *Myxobolus squamaphilus* sp. n. (Myxozoa: Myxosporea), a Common Parasite of the Scales of Bream (*Abramis brama* L.)

Kálmán MOLNÁR

Veterinary Medical Research Institute, Hungarian Academy of Sciences, Budapest, Hungary

**Summary.** *Myxobolus squamaphilus* sp. n. (Myxosporea: Myxozoa) is a common parasite of bream (*Abramis brama*) in Lake Balaton and the River Danube. Its lentil-shaped, relatively small plasmodia develop in the connective tissue consisting of collagen fibrils on the surface of the cartilaginous plate of scales. Mature plasmodia containing only a few hundred spores can be detected in the fish in April and May. In March primarily the developing stages while in the early summer the traces left by excreted plasmodia can be detected in the scales. In the spring months, the prevalence of infection exceeds 50% while its intensity may reach 7 per scale. By its ellipsoidal, relatively large spores this species is well distinguishable from other species known from the bream and from other cyprinids.

**Key words:** *Abramis brama*, *Myxobolus*, Myxosporea, new species, scales.

### INTRODUCTION

Different *Myxobolus* species occur in diverse locations within the host organism. Numerous species parasitise the skin of fish, and several of them (*M. caudatus*, *M. lobatus*, *M. niei*) establish themselves in the external layer of the integument. Some of the latter, such as the barbel parasites *M. squamae* and *M. cutanei*, the rainbow trout parasite *M. squamalis*, and *M. squamosus* described from *Hybopsis kentuckiensis* form plasmodia on the scales as a typical location (Keysselitz 1908, Kudo 1934, Iversen 1954, Alvarez-Pellitero and Gonzalez-Lanza 1985). Egusa et al. (1990) observed a *Myxobolus* infection on the scales of the mullet (*Mugil cephalus*) and, based upon the typical location of cysts, described the causative species as *M. episquamalis*. While Shulman

(1966) listed 14 *Myxobolus* species as being parasitic in bream (*Abramis brama*), Landsberg and Lom (1991) recorded only 7 species which had been described originally from bream. In Hungary, *Myxobolus* infection of bream living in Lake Balaton was studied by Jaczó (1940) who, in addition to the already known *M. muelleri*, reported two additional species (*M. hungaricus* and *M. variabilis*) from the gills of bream. Data on the parasite fauna of Lake Balaton bream can be found in a paper by Molnár and Székely (1995).

The present paper describes a *Myxobolus* species occurring specifically on the scales of bream (*Abramis brama*).

### MATERIALS AND METHODS

During a survey of the parasite fauna of bream living in Lake Balaton, a total of 60 breams were subjected to parasitological examination in 1994 (Molnár and Székely 1995), 41 in 1995, and 61 in 1996. The

Address for correspondence: Kálmán Molnár, Veterinary Medical Research Institute, Hungarian Academy of Sciences, P.O.Box 18, H-1581 Budapest, Hungary; Fax:(36-1)252-1969; E-mail: kalman@novell.vMRI.hu

Table 1. Seasonal occurrence of *M. squamaphilus* on the scales of bream in Lake Balaton and River Danube

Month	Number of infected fish						Number of uninfected fish		
	Young plasmodia			Plasmodia with spores			1994	1995	1996
February								2	
March			2						2
April	3		3	3	2	1	12		5
May	4			3	5	8	4	3	3
June							8	13	5
July				3			4		10
August							3	2	4
September							5	2	5
October								12	11
November							12		

body length of the fish was 14–38 cm. Thirty scales were removed from the dorsal part of each dissected fish, and examined under stereomicroscope for the presence of *Myxobolus* cysts. The infected scales were

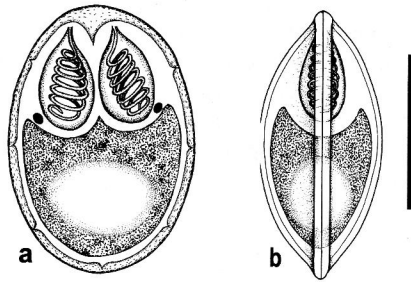


Fig. 1. Schematic drawing of the spores of *Myxobolus squamaphilus*. (a) - upper view, (b) - lateral view, bar - 10 µm

placed on a slide and examined in a light microscope at 100-fold magnification. The measurements of cysts were taken, the location of plasmodia on the scales was recorded, and the stage of maturity of plasmodia was determined. Spores were released from the spore-containing plasmodia with the help of a dissecting needle, then some of them were examined fresh while others were placed into glycerol-gelatin and processed into a permanent preparation. For histological examination, samples of infected scales were fixed in 10% buffered formalin or in Bouin's solution. To avoid epithelial injuries during scale removal and to determine the location of plasmodia more closely, large scale-covered skin pieces from the infected area were also fixed in the above solutions. The fixed samples were embedded in paraffin and cut into 4 µm thick sections which were stained with haematoxylin and eosin (H.-E.) and by the Giemsa stain. The measurements of spores were determined by comparing images of spores projected from an Olympus microscope to the screen of a video recorder with a computer-calibrated scale of measurements. The photomicrographs were taken with the help of a Jenaval photomicroscope.

## RESULTS

Three *Myxobolus* species were consistently found in breams in Lake Balaton. The species *Myxobolus bramae* Reuss, 1906 was often detected in the form of small plasmodia located at the tips of the gill filaments. Less frequently a species forming large plasmodia occurred in a region close to the base of gill filaments. The spores of this latter species were identified as *M. hungaricus* Jacsó,

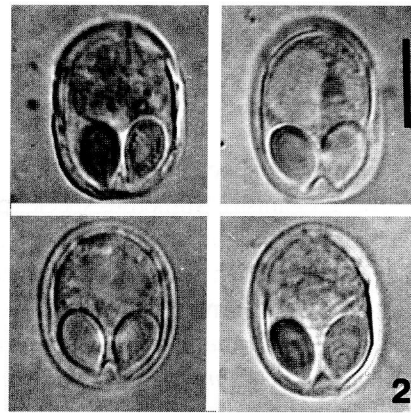


Fig. 2. Spores of *M. squamaphilus*, bar - 10 µm

1940. A hitherto unknown parasite, differing from the previously described species in cyst location and spore shape, was often found in the same fish. The plasmodia of this *Myxobolus* species were present in any location on those parts of the scales which were not covered by the neighbouring scales. In intensive infection, as many as

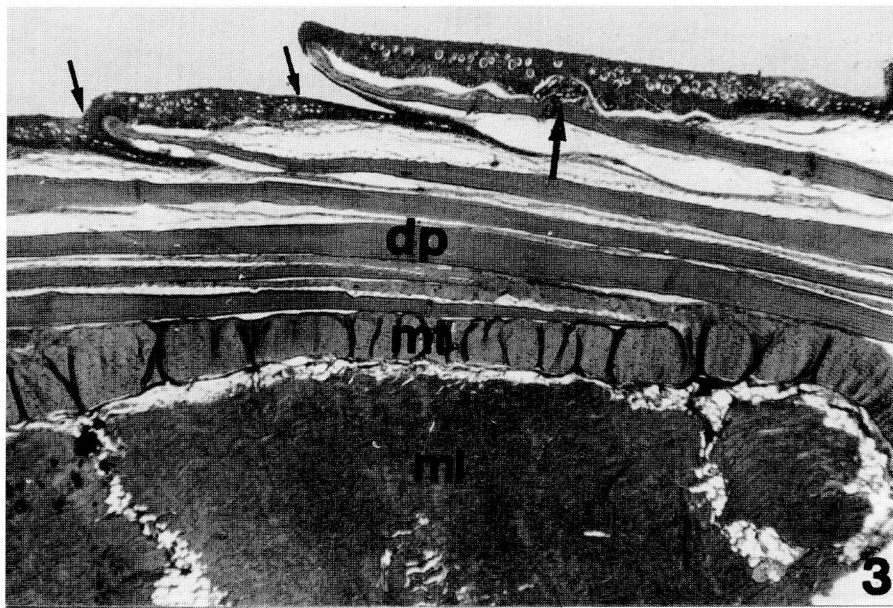


Fig. 3. Section of scales infected by *Myxobolus squamaphilus* plasmodia from bream. Cross section of the scaly skin and muscle: epidermis and its portion bent back under the scales (arrows); *Myxobolus* plasmodium (large arrow); dermis interwoven with calcified scale plates (dp); transversely running muscle bundles (mt); longitudinally running muscle bundles (ml). H.-E. (x40)

7-9 plasmodia were found on a single scale, and almost all scales proved to be infected. In less intensive infection, however, only a few scales were infected by single plasmodia.

The lentil-shaped plasmodia measuring 0.1–0.3 mm in diameter were located episquamally on the surface of the cartilaginous plate of the scales, and could be dislodged from there after epithelium removal. In majority of cases plasmodia were damaged during the removal, releasing spores or vegetative forms.

Plasmodia developing on scales were usually found on the fish since April; in one case, however, they were detected as early as March (Table 1). During the dissection of fish in April and May, *Myxobolus* plasmodia were detected on the scales of 13 out of 29 breams in 1994, 7 out of 10 breams in 1995, and 12 out of 20 breams in 1996. Subsequently the number of positive cases rapidly decreased, and only 3 out of 17 breams examined up to the end of August were found to be infected in 1994, while in the same period of 1995 no scale myxobolosis occurred at all. In fish examined in autumn, plasmodia were found only on a single occasion, in October 1996. Plasmodia examined at the beginning of April already contained mature spores; however, the majority of plasmodia still contained vegetative stages. Since the end of April, however, plasmodia were filled exclusively by mature spores (Figs. 1, 2). These relatively small plasmodia

contained relatively few, 50 to 200, spores which, however, were large in size. In the summer months, small, round, transparent spots were often seen on the scales: these were of the same size as the plasmodia, and probably represented traces left behind by excreted plasmodia. The plasmodia found on a single occasion in the autumn were filled by spores containing a disintegrated sporoplasm.

Histologically, the integument of the bream was found to be similar to that of other scaly fish (Hawkes 1974, Lanzing and Wright 1976). The base of the scales is constituted by a calcified plate formed by the surrounding collagenous connective tissue. The external surface of the layer composed of collagen fibrils is bordered by a basal membrane covered by stratified epithelium. At the tip of the scales the epithelial layer turns back and covers part of the calcified collagen (cartilaginous) plate also from underneath (Fig. 3). In further parts of the plate, however, the plate-forming collagenous connective tissue is connected with the underlying plate of the scale by loose connective tissue. Beneath the overlapping scale plates, a layer of loose connective tissue binds the dermis together with the transversely or longitudinally running bundles of muscle fibres (Fig. 3). The plasmodia were always found in the corium layer composed of collagen fibrils running episquamally on the external surface of the calcified scale plate (Fig. 4). In some cases a capsule consisting of collagen fibrils had been formed around the plasmodia

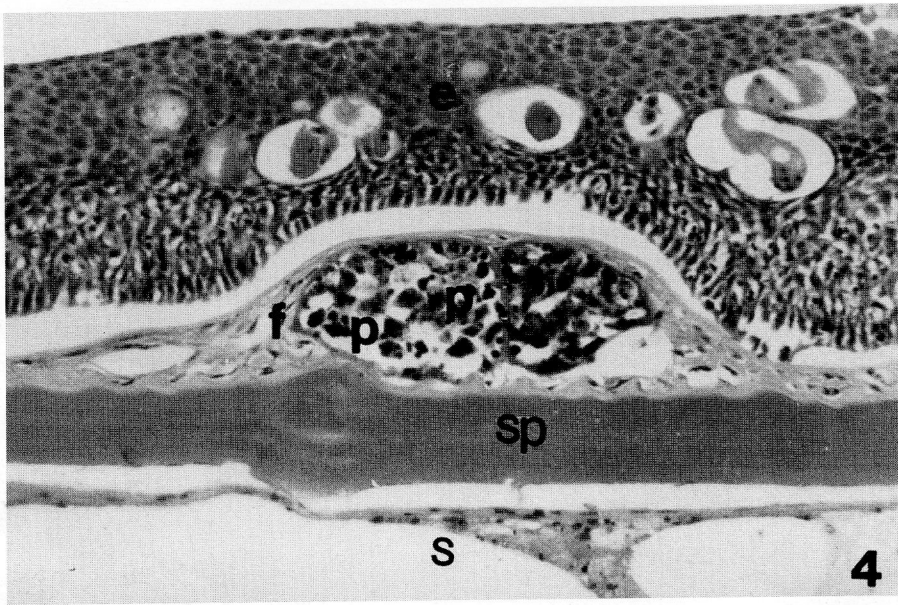


Fig. 4. Section of scales infected by *Myxobolus squamaphilus* plasmodia from bream. Location of *M. squamaphilus* plasmodium in the dermis: (e) cells of stratified epithelium with goblet cells; (f) fibrocyte layer rich in collagen fibrils in the dermis; (p) plasmodium; (sp) calcified scale plate; (s) subsquamal layer of dermis. H.-E. (x400)

(Figs. 4, 5). Scleroblast cells constituting the scale plates were not involved in the formation of the capsule. The collagenous capsule often grew very thin around plasmodia containing mature spores, and the plasmodium came into close contact with the basal membrane bordering the epidermis (Fig. 5).

#### Description of the newly found *Myxobolus* species:

*Myxobolus squamaphilus* sp. n. (Figs. 1, 2)

Type host: *Abramis brama* L.

Locality: Lake Balaton (Keszthely, Fonyód, Balatonszemes, Tihany, Csopak regions), River Danube (Surány, 30 km north of Budapest).

Site of infection: episquamal region of the connective tissue of the scales.

Type material: holotype deposited in the protozoan collection of the Zoological Department, Hungarian Natural History Museum. Coll. No. 671.

Description of the species: spores (Figs. 1, 2) relatively large, typically ellipsoidal with distinct sutural line. Spore valves symmetrical, smooth, with several sutural edge markings. Spores are 18.7 (17–19.5)  $\mu\text{m}$  long, 13.6 (13–14)  $\mu\text{m}$  wide and 11.5 (11–12)  $\mu\text{m}$  thick. Two polar capsules, pyriform in shape, tapering only at the discharging canals of the polar filament. They are equal in size, 6.8 (6.5–7.0)  $\mu\text{m}$  long and 4.2 (4–4.5)  $\mu\text{m}$  wide. The spore has a large triangular intercapsular appendix. Polar fila-

ments closely coiled with 7 turns in the polar capsule, situated perpendicularly or subperpendicularly to the longitudinal axis of the capsule. A large distinct iodophilous vacuole was found in the sporoplasm.

Differential diagnosis: different barbel species are the cyprinids best known to have parasitic *Myxobolus* species on their skin and scales. Of scale-parasitic myxosporeans, *M. squamae* living on the scales of barbel (*Barbus barbus*) is the best studied parasite. The species found on bream differs from the latter species in its markedly larger size and in the dissimilar location of plasmodia. While *M. squamaphilus* develops in the collagenous connective tissue of the scales, on the surface of the cartilaginous plate, the plasmodia of *M. squamae* are formed in deep layers of the chondrified substance. The new species described here also differs from *M. caudatus* reported from Central Asian barbel species and from *M. cutanei* detected from the scales of *Barbus barbus bocagei*, probably synonymous with the former. Namely, the latter species has a "racket-shaped" mucoid process at the caudal end of the spores. By their characteristically oval shape, the spores of *M. episquamalis* markedly differ from the mostly ellipsoidal spores of *M. squamaphilus*. Although *M. squamosus* resembles *M. squamaphilus* in spore shape, the spores of the former species have two narrow parallel ridges running parallel to the sutural ridge. In spore morphology, *M. squamaphilus* shows the highest degree of similarity with the species

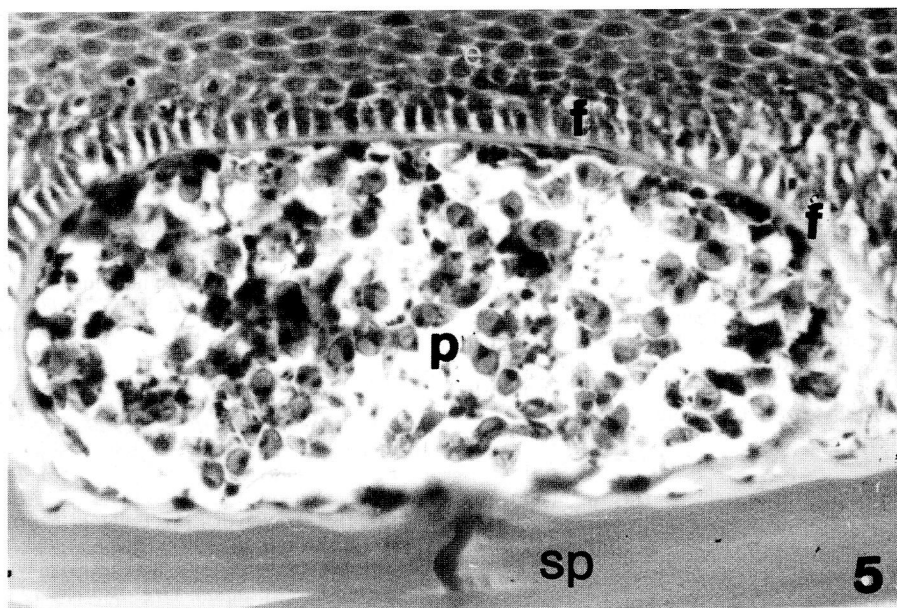


Fig. 5. Section of scales infected by *Myxobolus squamaphilus* plasmodia from bream. Episquamal plasmodium filled with spores and surrounded by a thinned-down collagenous capsule under the epithelium. (e) epithelium; (f) fibrocyte layer; (p) plasmodium; (sp) calcified scale plate. H.-E. (x800)

*M. cycloides* Gurley, 1894 described from bream, but is distinguishable from the latter species by its larger size, different host spectrum and location within the host.

## DISCUSSION

Different *Myxobolus* species are common parasites of cyprinids and especially of the bream. Thus, it is surprising that in Lake Balaton, where more than half of the fish population is constituted by the bream, only three species have been recorded, one of which is the species described here. *Myxobolus squamaphilus* differs from *Myxobolus* species occurring in other cyprinids in both morphology and location. In addition to the morphological characteristics, knowledge of the host, organ and tissue specificity of a given parasite species is considered very important in the identification of myxosporeans (Molnár 1994). *Myxobolus squamaphilus* is a typical scale parasite whose specific location is the collagen fibril network covering the calcified plate of the scales. The parasite greatly resembles the species *M. squamae* in location; however, the plasmodia of the latter species (Baska unpublished) develop in a cavity formed in the cartilaginous plate rather than episquamally, in a manner similar to that described by Iversen (1954) for the species *M. squamalis*. In its location, *M. squamaphilus* is most similar to *M. episquamalis*

which, according to Egusa et al. (1990), also forms cysts apically on the surface of the ossifying plate of scales. While, however, *M. squamaphilus* forms small, uniform cysts in different areas of the calcified plate, *M. episquamalis* forms a mass consisting of cysts on the outer surface of the bony scale plate. These plasmodia are abundant in septa consisting of collagen fibrils and even blood vessels; at the same time, the plasmodia penetrate the calcified plate, causing small erosions. According to Moshu and Molnár (1997), in the European wild carp (*Cyprinus carpio carpio*) the plasmodia of the otherwise fin-parasitic *Thelohanellus nikolskii* can be found also on the scales. These plasmodia, however, always start to develop in a yet non-calcified plate area at the margin of the scale, and then develop in a cartilaginous capsule formed by scleroblast cells. A common characteristic of all three parasites is their affinity to collagen. *Myxobolus squamaphilus* typically occurs in the spring, and spore formation is practically completed by the end of April. Most spores are released in the summer through skin injuries caused by the bursting of plasmodia. The sites of spore release are seen as tissue-less areas on the scales. In some cases, spore-containing plasmodia may occur on the scales also in other periods of the year; these, however, always contain aged spores. Signs of regenerative processes are often seen around aged and non-emptied plasmodia of numerous species. Both in *M. basilamellaris*

infection of the common carp and in *M. kottlani* infection of the eel, granulation tissue consisting of histiocytes was found to proliferate into the aged plasmodia, infiltrating and destroying the spores (Kovács-Gayer and Molnár 1983, Molnár et al. 1986). No such regenerative activity could be observed in *M. squamophilus* infection, probably because the plasmodia enclosed in collagenous substance were inaccessible for the histiocytes.

**Acknowledgements.** The author wish to thank Dr Cs. Székely and Ms. Emese Papp for helping in collection of fish. Financial support to this work was provided by the National Research Fund (OTKA) project no. T 014648, the US-Hungarian Joint Research fund, J. F. 326, and the Fish Management Fund of the Ministry of Agriculture.

## REFERENCES

- Alvarez-Pellitero M. P., Gonzalez-Lanza M. C. (1985) Studies on *Myxobolus* spp. of *Barbus barbus bocagei* from the river Esla (Leon, NW Spain). *Angew. Parasitol.* **26**: 3–12
- Egusa S., Maeno Y., Sorimachi M. (1990) A new species of Myxozoa, *Myxobolus episquamalis* sp. nov. infecting the scales of the mullet, *Mugil cephalus* L. *Fish Pathol.* **25**: 87–91
- Hawkes J. W. (1974) The structure of the fish skin I. General organisation. *Cell Tiss. Res.* **149**: 147–158
- Iversen E. S. (1954) A new myxosporidian, *Myxosoma squamalis*, parasite of some salmonid fishes. *J. Parasitol.* **40**: 169–178
- Jaczó I. (1940) Investigations on myxosporeans of fishes in Lake Balaton. I. *Magy. Biol. Kut. Int. Munkái* **12**: 277–290 (in Hungarian)
- Keysselitz G. (1908) Über durch Sporozoen (Myxosporidien) hervorgerufene pathologische Veränderungen. *Verh. Ges. Deutsch. Naturforsch. und Ärtz. Vers.* **79**: 452–453
- Kovács-Gayer É., Molnár K. (1983) Studies on the biology and pathology of the common carp parasite *Myxobolus basilamellaris* Lom et Molnár, 1983 (Myxozoa: Myxosporea). *Acta Vet. Hung.* **31**: 91–102
- Kudo R. R. (1934) Studies on some protozoan parasites of fishes of Illinois. III. *Biol. Monogr.* **13**: 1–41
- Landsberg J., Lom J. (1991) Taxonomy of the genera of the *Myxobolus/Myxosoma* group (Myxobolidae: Myxosporea), current listing of species and revision of synonyms. *Syst. Parasitol.* **18**: 165–186
- Lanzing W. J. R., Wright R. G. (1976) The ultrastructure and calcification of the scale of *Tilapia mossambica*. *Cell Tiss. Res.* **167**: 37–47
- Molnár K. (1994) Comments on the host, organ and tissue specificity of fish myxosporeans and on the types of their intrapiscine development. *Parasit. Hung.* **27**: 5–20
- Molnár K., Lom J., Malik E. (1986) A skin disease of the eels caused by *Myxobolus kottlani* n. sp. *J. Appl. Ichthyol.* **2**: 42–48
- Molnár K., Székely Cs. (1995) Parasitological survey of some important fish species of Lake Balaton. *Parasit. Hung.* **28**: 63–82
- Moshu A., Molnár K. (1997) *Thelohanellus* (Myxozoa: Myxosporea) infection of the scales in the European wild carp, *Cyprinus carpio* L. *Dis. aquat. Org.* **28**: 115–123
- Shulman S. S. (1966) Myxosporidia of the Fauna of the USSR. Nauka, Moscow–Leningrad (in Russian)

Received on 3rd February, 1997; accepted on 2nd June, 1997