

CUTANEOUS SPHAEROSPOROSIS OF THE COMMON CARP FRY

By

K. MOLNÁR

Veterinary Research Institute, Hungarian Academy of Sciences, Budapest

(Received April 8, 1980)

Branchial and renal sphaerosporosis of the common carp fry in Hungary, caused by *Sphaerospora carassii* Kudo, 1919 (*Protozoa: Myxosporidia*) and *S. angulata* Fujita, 1912, respectively, was reported earlier in this Journal and elsewhere (MOLNÁR, 1978, 1979).

In more recent studies, we have detected many sphaerospora stages in cutaneous scrapings obtained from young carps and investigated the condition in detail. The results are reported in this paper.

Materials and methods

Eighty 1 to 3 months old carps, and 156 3—6 months old carp fry, obtained from different pond farms, were examined above all for the frequency of renal sphaerosporosis. About 90% of the carps were mirror carps, the rest were scaled specimens. The incidence of concurrent infections was studied in impression smears of organs other than the kidney, and in scrapings from the gill and skin. The organs infected by sphaerospora stages or, if the host was small, the fish *in toto*, were fixed in 10% formalin or Bouin solution, embedded in paraffin, and cut to 3—6 μ m thick sections. From *in toto* processed fish not longer than 1.5—2 cm, longitudinal sections were cut to include details of gills, skin and kidney in a single section. The sections were stained with haematoxylin and eosin, or with the Farkas—Mallory technique.

Results

Of the 80 1—3-summer carps, 16 harboured *S. carassii* spores in the gills, and 2 had *S. angulata* spores in the kidney. Histological evidence of cutaneous sphaerosporosis was obtained only later, and only this prompted us to scrutinize the cutaneous scrapings. Nine hosts, all with gill sphaerosporosis, were found to harbour the parasite in cutaneous locations as well. Renal sphaerosporosis was not associated with gill or skin involvement in either case. Of the

156 3—6 months old carps 36 had a renal *S. angulata* infection, but neither gill nor skin sphaerosporosis occurred in this age group.

The spores detected in the skin were similar in shape and size to those established in the gills, but differed from those found in the kidney.

The histological examinations showed that the massive infection spread from the gill filament and gill-arch epithelium to the lining epithelium of the gill cavity, which was packed with spores and developmental stages everywhere except in the thymic area. The infection was similarly massive in the skin surrounding the branchial slit, but much milder in the areas adjoining the dorsal and abdominal fins. Spores were occasionally found in the skin of the head, exclusively in those areas where the epithelium was thick. No parasites were detected in the epithelium of the operculum and in the skin covering the posterior part of the body.

In the cutaneous areas adjoining the branchial slit, the cutaneous epithelium was uniformly infected from the stratum germinativum to the surface. Developmental stages occurred only near the stratum germinativum, but spores were detected over the entire thickness of the epithelium (Fig. 1). In the cutaneous epithelium of the head and central part of the body, spores occurred only in minor islet-like aggregations (Fig. 2). In the massively infected cutaneous regions, the structure of the epithelium became rarefied, and part of the epithelial cells showed a serous degeneration. The surface of the epithelium was covered by damaged cells and structureless cell debris.

Discussion

The present studies have shown that *S. carassii*, formerly regarded as exclusively a gill parasite, is also responsible for a cutaneous sphaerosporosis, which involves not only the stratified epithelium of the gill filaments and gill arches, but also the lining epithelium of the gill cavity and certain cutaneous areas of the body of carps. There is reason to postulate that sphaerosporosis of the gills is always associated with a cutaneous involvement, although evidence of this could be obtained only in 1 to 3 months old carps in the present study.

The histological examinations have shown that gill and skin involvement are always continuous. Since among the scaled carps included in the study none harboured sphaerospores, it might be questioned whether the parasite could establish itself in a scaly skin at all. It also remains to be clarified how long the cutaneous sphaerosporosis might persist, for among the hosts included in the study only the less than 3 months old fry was infected with *S. carassii*. It is known from earlier studies (MOLNÁR, 1979) that the sphaerosporosis of the gill may persist longer than 4 months in infected hosts. There is reason to postulate that the cutaneous infection takes a similarly long course.

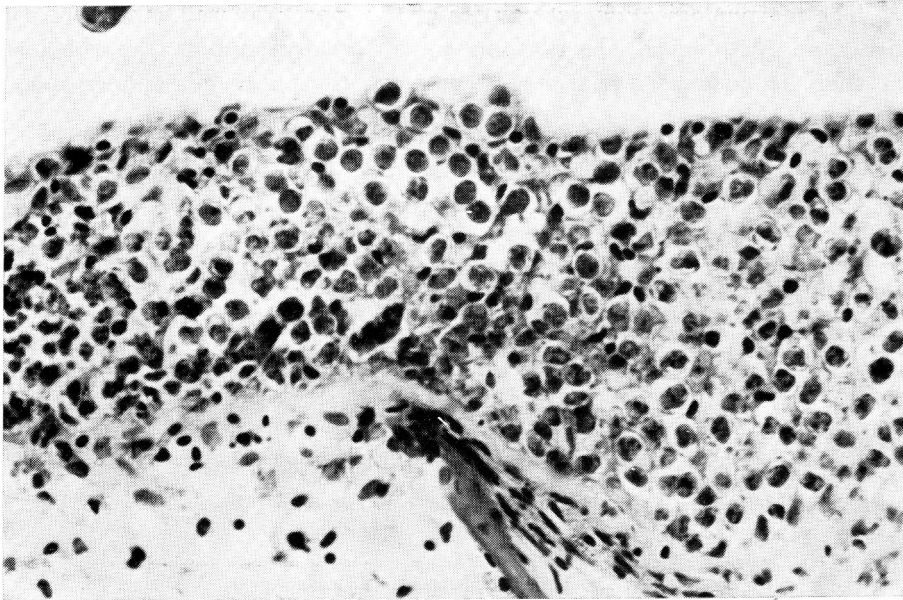


Fig. 1. Spores and developmental stages in the skin of a carp fry

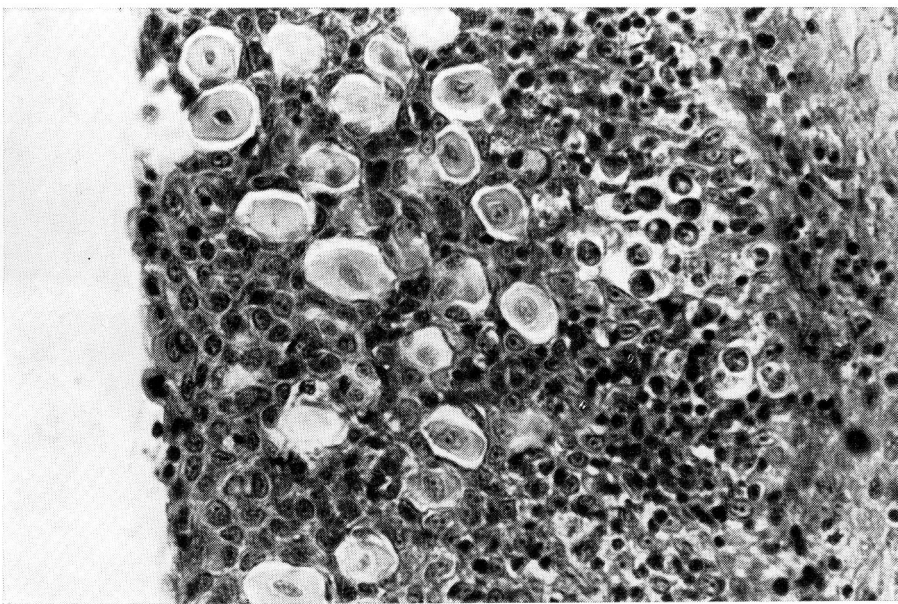


Fig. 2. Islet-like aggregations of *S. carassii* spores in the cutaneous epithelium

The morphological characteristics of the spores, as well as the epizootological and histological observations unequivocally support the conclusion that there is no causal relationship between the cutaneous sphaerosporosis and the renal *S. angulata* infection of fish hosts.

Summary

The cutaneous sphaerosporosis of the common carp fry is caused by *Sphaerospora carassii* Kudo, 1919, which also accounts for gill sphaerosporosis in the same host. Spores and developmental stages of *S. carassii* were detected in large numbers in cutaneous areas near the gills of 1–3 months old carp fry.

References

- MOLNÁR, K. (1979): Gill sphaerosporosis in the common carp and grasscarp. *Acta vet. hung.* **XXVII**, 99–113.
- MOLNÁR, K. (1980): Renal sphaerosporosis in the common carp (*Cyprinus carpio* L.). *J. Fish Dis.* **3**, 11–19.

Address of the author: Dr. Kálmán MOLNÁR, 1581 Budapest, P.O. Box 18, Hungary.