



## A survey on coccidian infection of Lake Biwa fishes in Japan, with the description of four new species of *Goussia* Labbé, 1896 (Apicomplexa)

K. Molnár<sup>1</sup> & K. Ogawa<sup>2</sup>

<sup>1</sup>Veterinary Medical Research Institute, Hungarian Academy of Sciences, H-1581 Budapest, PO Box 18, Hungary

<sup>2</sup>Department of Aquatic Bioscience, Graduate School of Agricultural and Life Sciences, the University of Tokyo, Yayoi 1-1-1, Bunkyo-ku, Tokyo 113-8657, Japan

Accepted for publication 3rd February, 2000

### Abstract

Thirty-two specimens of 11 freshwater fish species from Lake Biwa, Japan were surveyed for coccidian infections. Four fish species proved to be infected with apicomplexans belonging to the genus *Goussia*. Altogether, seven *Goussia* species were found. Oöcysts of four species inhabiting the intestinal epithelium were shed at the sporulated stage. Two other intestinal species left the fish unsporulated. A few relatively large and aged oöcysts of a further species were found in the renal tubules. The sporulated intestinal species were described as *Goussia biwaensis* n. sp., *G. grygieri* n. sp., *G. nipponica* n. sp. and *G. wakabayashii* n. sp.

### Introduction

The coccidian fauna of Japanese fishes has been poorly studied. Fujita (1934) described *Eimeria nishin* from the herring of the Sea of Japan. Dogiel (1948) recorded six other eimeriid species [*E. auxidis* Dogiel, 1948, *E. citriformis*, Dogiel, 1948, *E. dogieli* (Dogiel, 1948) Pellérdy, 1963, *E. etrumei* Dogiel, 1948, *E. evaginata*, Dogiel, 1948 and *E. pneumatophori* Dogiel, 1948] from fishes in the Sea of Japan. Coccidia from freshwater fishes include *Goussia subepithelialis* (Moroff & Fiebiger, 1905) and *G. carpelli* (Léger & Stankovitch, 1921) from farmed common carp (Tokumori et al., 1985), and the pathogenic effect of *Eimeria truttae* (Léger & Hesse, 1919) has been described by Awakura et al. (1983) from Masu salmon.

Unlike the Japanese fauna, fish coccidia from freshwater fishes of the Amur-Chinese Fauna Region are relatively well studied, and several species have been described from that biotope. In China, Chen (1956a, b) first described two species of *Eimeria* Labbé, 1896 from black and silver carp, respectively, and 13 species of fish coccidia were recorded in a review of Chinese fish parasites edited by Chen (1973). Later, Su & Chen (1987) and Li & Nie (1995) added five new species to that list. From the River Amur, Dogiel & Achmerov (1959) and Shulman & Zaika

in Shulman & Shtein (1962) described a further six *Eimeria* species.

This paper describes a survey of coccidian infections of Lake Biwa fishes in Japan, which resulted in finding seven *Goussia* species, four of which are described as new.

### Materials and methods

Lake Biwa is the largest freshwater lake in Japan. It is inhabited by 57 fish species, including 11 indigenous species (Mori & Miura, 1990). In a survey conducted in June 1999, 32 specimens of fish belonging to 11 species [*Pseudogobio esocinus* (Temminck & Schlegel) (4), *Gnathopogon elongatus caerulescens* (Sauvage) (4), *Tribolodon hakonensis* (Günther) (3), *Anguilla japonica* Temminck & Schlegel (1), *Rhinogobius* sp. (3), *Cottus reini* Hilgendorf (2), *Tridentiger kuroiwaie brevispinis* (Katsuyama, Arai & Nakamura) (3), *Opsariichthys uncirostris uncirostris* (Temminck & Schlegel) (3), *Hemibarbus barbus* (Temminck & Schlegel) (3), *Rhodeus ocellatus ocellatus* (Kner) (3) and *Tanakia limbata* (Temminck & Schlegel) (3)] were examined for coccidian infections. Fish were caught with traps, carried to the Lake Biwa Museum and maintained in aerated aquaria for some days until

coarse faecal particles were voided. The fish were killed, by cutting off their heads with scissors, and the intestinal tract and other visceral organs were examined for infection. Pieces of visceral organs were squashed under a coverslip on a glass slide, and mucus and epithelial scrapings were examined from the intestine. When infection was found, at least 25 oöcysts were studied. Measurements were taken under a compound microscope and freehand drawings were made immediately after the oöcysts had been detected. All measurements are in micrometres ( $\mu\text{m}$ ), given as a mean followed by the range in parentheses.

## Results

Altogether four of the 11 examined fish species were infected by coccidians. All coccidians were found belonged to the genus *Goussia*. Of the fishes infected by coccidia, *Pseudogobio esocini* harboured two intestinal and a renal species, *Hemibarbus barbus* had two, and *Tribolodon hakonensis* and *Tridentiger kuroi* had one species each in the gut. In most of the fish, sporulated oöcysts were found in the transparent intestinal mucus but less often in the epithelial scrapings and in the gut contents. An exception was *Hemibarbus barbus*, in which only unsporulated oöcysts were found. Of the species having sporulated oöcysts four proved to be new.

### *Goussia biwaensis* n. sp.

*Type-host*: *Pseudogobio esocinus* (Temminck & Schlegel); Cyprinidae.

*Type-locality*: Mano, Lake Biwa, Shiga Prefecture, Japan.

*Site*: Mucus and epithelium of the foregut.

*Prevalence of infection*: Four infected specimens, 100%.

*Intensity of infection*: Moderate.

*Type-material*: Phototypes have been deposited in the parasitological collection of the Hungarian Natural History Museum, Budapest. Coll. No. HNHM-67388.

*Etymology*: The *nomen triviale* derives from the name of the lake.

*Description* (based upon 25 sporulated oöcysts) (Figure 1)

Oöcysts (Figure 1) spherical, 8.5 (8–9). Wall of the oöcyst smooth, colourless and thin. Micropyle and

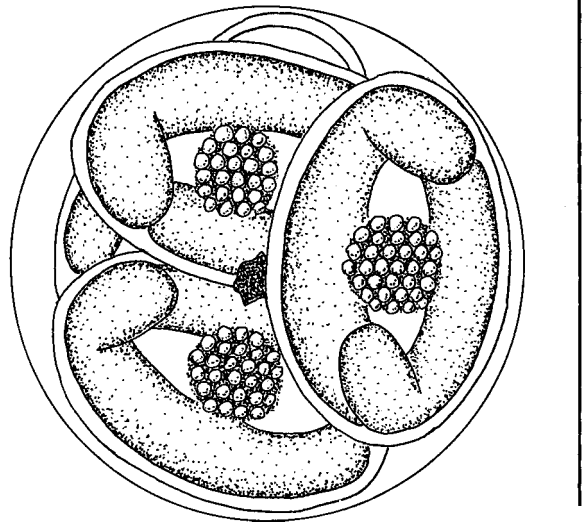


Figure 1. Oöcyst of *Goussia biwaensis* n. sp. Scale-bar: 10  $\mu\text{m}$ .

oöcyst residuum absent; polar granule amorphous, small but bright, with diameter of 1, located in most cases in centre of oöcyst. Oöcysts contain 4 ellipsoidal sporocysts which are slightly pointed at ends and compactly fill oöcyst space, arranged in oöcysts so that 3 sporocysts are seen in one plane. Size of sporocysts 5.6 (5–6)  $\times$  3.8 (3.5–4.0). Sporocyst wall very thin, single-layered. Two sporocyst valves are connected by indistinct, longitudinally running suture. Stieda-body or Stieda-body-like formation not seen. Sporozoites vermiform with reflexed end, aligned head to tail in sporocyst, measure 6.7 (6.5–7.0)  $\times$  1.4 (1.0–1.5). Sporocyst residuum globular or ellipsoidal, finely granulated, c. 3  $\times$  2 in young oöcysts, compact or scattered in mature oöcysts.

Oöcysts pass from gut sporulated.

### Remarks

In its morphology and size *Goussia biwaensis* n. sp. resembles species of the “carpelli type” [*G. carpelli* Leger & Stankovitch, 1921, *G. legeri* Stankovitch, 1920, *G. iroquoina* (Molnár & Fernando, 1974)] but differs from them by having a bright, distinct polar granule.

### *Goussia grygieri* n. sp.

*Type-host*: *Pseudogobio esocini* (Temminck & Schlegel); Cyprinidae.

*Type-locality*: Mano, Lake Biwa, Shiga Prefecture,

Japan.

*Site:* Mucus and epithelium of the foregut.

*Prevalence of infection:* One infected specimen, 25%.

*Intensity of infection:* Moderate.

*Type-material:* Phototypes have been deposited in the parasitological collection of the Hungarian Natural History Museum, Budapest. Coll. No. HNHM-67386.

*Etymology:* The species was named for Mark J. Grygier, associate research scientist at Lake Biwa Museum, whose scientific and technical help greatly contributed to the successful results of the survey.

*Description* (based upon 25 sporulated oöcysts) (Figure 2)

Oöcysts (Figure 2) spherical, 10.4 (10–11) in diameter. Wall of the oöcyst smooth, colourless and thin. Micropyle, oöcyst residuum and polar granule absent. Oöcysts contain 4 sporocysts, which compactly fill oöcyst space and are arranged in oöcysts so that 2 sporocysts lie in one plane. Sporocysts exhibit different shape in upper view and side view; in upper view sporocysts are typically ellipsoidal, while in side view one of their longitudinal sides is flattened. Length of sporocysts 9.5 (9–10); width and thickness 5.0 (4.5–5.5). Sporocyst wall very thin, single-layered. Two sporocyst valves are connected by indistinct, longitudinally running suture. Stieda-body or Stieda-body-like formation not seen. Sporozoites vermiform, with reflexed end located head to tail in sporocyst, measure 12 (11–13)  $\times$  1.5 (1.0–2.0). Sporocyst residuum globular or ellipsoidal, finely granulated, c. 3  $\times$  2.5 in younger oöcysts.

Oöcysts pass from gut sporulated.

#### Remarks

In its morphology the oöcyst of *Goussia grygieri* n. sp. resembles *G. laureleus* (Molnár & Fernando, 1974), a parasite of the yellow perch, but it is smaller in size and the hosts are unrelated.

#### *Goussia* sp. I

*Host:* *Pseudogobio esocinus* (Temninck & Schlegel); Cyprinidae.

*Locality:* Mano, Lake Biwa, Shiga Prefecture, Japan.

*Site:* Kidney.

*Prevalence of infection:* One infected specimen, 25%.

*Description* (based upon 11 sporulated oöcysts) (Figure 3)

Oöcysts (Figure 3) ellipsoidal, 30 (28–32) long and 24 (20–27) wide. Wall of the oöcyst smooth, colourless and thin. Micropyle, oöcyst residuum and polar granule absent. Oöcysts contain 4 elongated ellipsoidal sporocysts, which loosely fill oöcyst space and are usually arranged in oöcysts in one plane. Length of sporocysts 18.4 (16–20); width and thickness 7.5 (7–8). Sporocyst wall very thin, single-layered. Two sporocyst valves are connected by indistinct, longitudinally running suture. Stieda-body or Stieda-body-like formation not seen. Sporozoites banana-shaped, located head to tail in sporocyst, measure 17 (16–18)  $\times$  2.7 (2.5–3.0). Sporocyst residuum ellipsoidal, finely granulated, c. 5  $\times$  8 (4–6  $\times$  7–9).

#### Remarks

*Goussia* sp. I resembles other parasites of the renal tubules, such as *G. leucisci* (Schulman & Zaika, 1964), *G. amurensis* (Dogiel & Achmerov, 1959) and *G. free-mani* (Molnár & Fernando, 1974), but differs from them in its larger size and the lack of polar granules. Due to the fact that during this survey only old oöcysts surrounded by macrophages were found in the blocked renal tubules, closer identification of the species was not possible.

#### *Goussia nipponica* n. sp.

*Type-host:* *Tribolodon hakonensis* (Günther); Cyprinidae.

*Type-locality:* Mano, Lake Biwa, Shiga Prefecture, Japan.

*Site:* Mucus and epithelium of the foregut.

*Prevalence of infection:* Three infected specimens, 100%.

*Intensity of infection:* Heavy.

*Type-material:* Phototypes have been deposited in the parasitological collection of the Hungarian Natural History Museum, Budapest. Coll. No. HNHM-67387.

*Etymology:* The nomen triviale derives from the name of the country.

*Description* (based upon 25 sporulated oöcysts) (Figure 4)

Oöcysts (Figure 4) spherical, 11 (10–12). Wall of oöcyst smooth, colourless and thin. Micropyle, polar granule and oöcyst residuum absent. Oöcysts contain

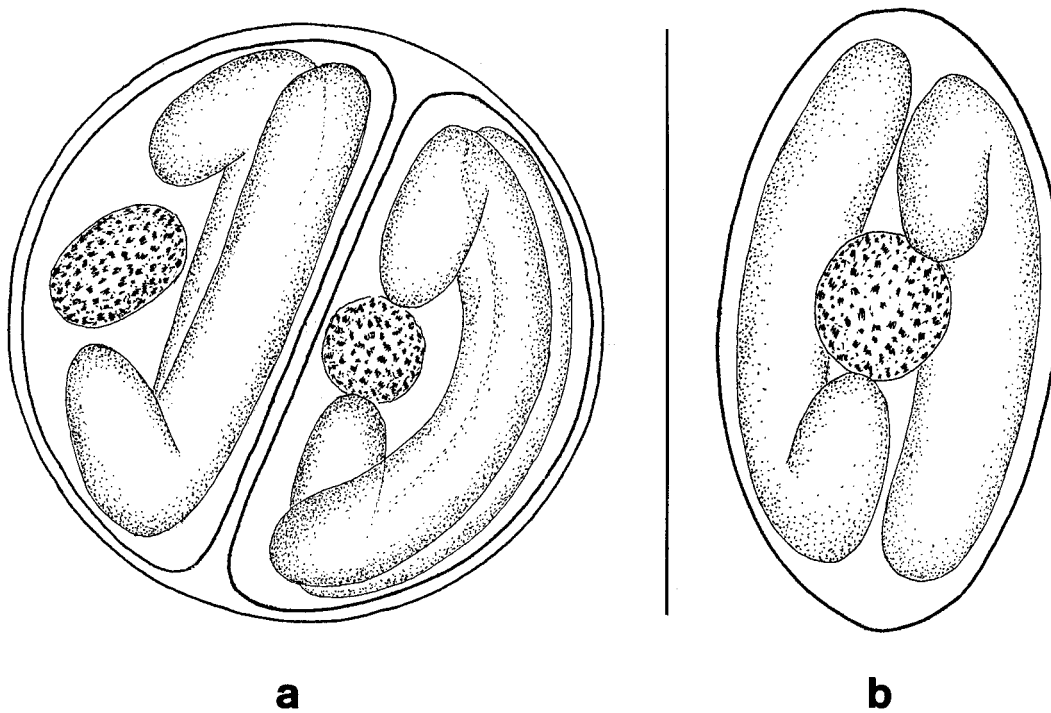


Figure 2. (a) Oöcyst of *Goussia grygieri* n. sp.; (b) Sporocyst of *G. grygieri* n. sp. Scale-bar: 10 µm.

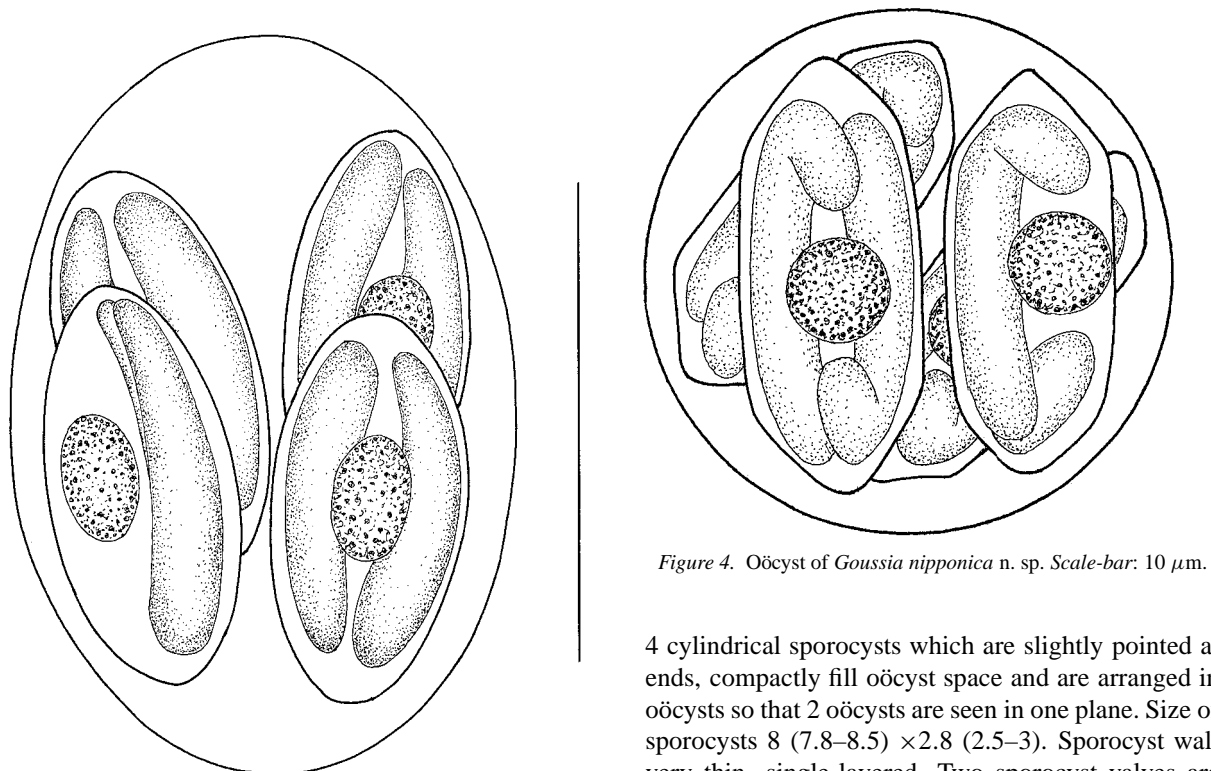


Figure 3. Oöcyst of *Goussia* sp. I. Scale-bar: 20 µm.

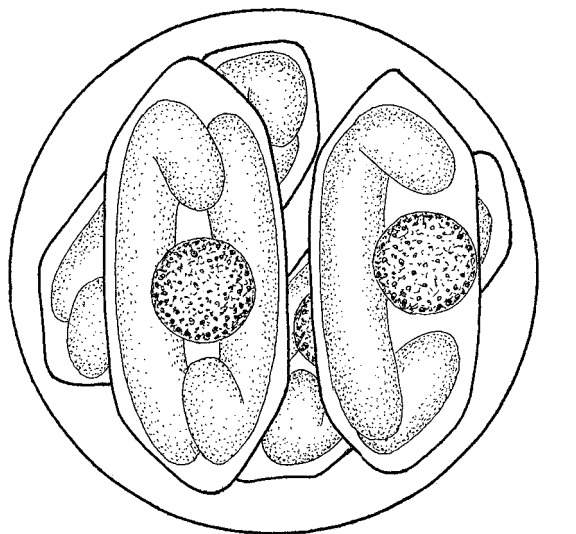


Figure 4. Oöcyst of *Goussia nipponica* n. sp. Scale-bar: 10 µm.

4 cylindrical sporocysts which are slightly pointed at ends, compactly fill oöcyst space and are arranged in oöcysts so that 2 oöcysts are seen in one plane. Size of sporocysts 8 (7.8–8.5) × 2.8 (2.5–3). Sporocyst wall very thin, single-layered. Two sporocyst valves are connected by indistinct, longitudinally running suture.

Stieda-body or Stieda-body-like formation not seen. Sporozoites vermiform, with reflexed end located head to tail in sporocyst, measure  $8.5 (8-9) \times 1.3 (1.0-1.5)$ . Sporocyst residuum globular or short ellipsoidal, finely granulated, measuring  $2 \times 2$  or  $2 \times 1$ .

Oöcysts pass from gut sporulated.

#### Remarks

In its sporocyst morphology this species resembles the sporocysts of *G. cylindrospora* (Stankovitch, 1921), *G. alburni* Stankovitch, 1920 and *G. siliculiformis* (Schulman & Zaika, 1962). It differs from the last two species by its smaller size. The sporocysts of *G. cylindrospora*, a specific parasite of the bleak *Alburnus alburnus* L., are about the same size as those of *G. nipponica*, but they are less slender and compact.

#### *Goussia wakabayashii* n. sp.

*Type-host*: *Tridentiger kuroiwae brevispinis* (Katsuyama, Arai & Nakamura); Gobiidae.

*Type-locality*: Mano, Lake Biwa, Shiga Prefecture, Japan.

*Site*: Gut content of the foregut.

*Prevalence of infection*: One infected specimen, 33%.

*Intensity of infection*: Low.

*Type-material*: Phototypes have been deposited in the parasitological collection of the Hungarian Natural History Museum, Budapest. Coll. No. HNHM-67389.

*Etymology*: The species was named for the well-known fish pathologist, Prof. D.H. Wakabayashi, University of Tokyo.

*Description* (based upon 25 sporulated oöcysts) (Figure 5)

Oöcysts (Figure 5) spherical  $8.5 (8-9)$  in diameter. Wall of oöcyst smooth, colourless and thin. Micropyle, polar granule and oöcyst residuum absent. Oöcysts contain 4 short, ellipsoidal sporocysts, which compactly fill oöcyst space and are arranged in oöcysts so that three oöcysts are seen in one plane. Size of sporocysts  $7 (6.5-7.5) \times 4.1 (3.8-4.3)$ . Sporocyst wall very thin, single-layered. Two sporocyst valves are connected by indistinct, longitudinally running suture. Stieda-body or Stieda-body-like formation is not seen. Sporozoites vermiform, with reflexed end, aligned head to tail in sporocyst, measure  $7.5 (7-9) \times 1.3 (1.0-1.5)$ . Sporocyst residuum globular, compact, c.  $1.0-1.5$  in diameter.

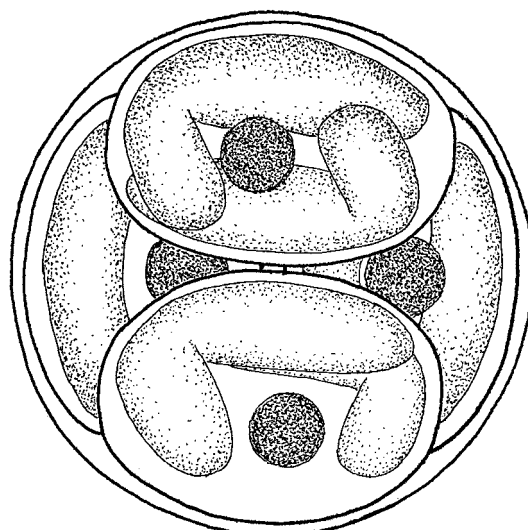


Figure 5. Oöcyst of *Goussia wakabayashii* n. sp. Scale-bar:  $10 \mu\text{m}$ .

Oöcysts pass from gut sporulated.

#### Remarks

The majority of gobiid fishes are infected by typical *Eimeria* spp.; however, the oöcysts of *G. wakabayashii* n. sp. found in the intestinal mucus showed typical *Goussia* characteristics.

#### *Goussia* sp. II

*Host*: *Hemibarbus barbus* (Temminck & Schlegel); Cyprinidae.

*Locality*: Mano, Lake Biwa, Shiga Prefecture, Japan.

*Site*: Gut content of the foregut, intestinal mucus and intestinal scrapings.

*Prevalence of infection*: Three infected specimens, 100%.

*Description* (based upon 25 unsporulated oöcysts) (Figure 6)

Only unsporulated oöcysts were found (Figure 6). Oöcysts ellipsoidal, measuring  $18 (17-19) \times 11 (10-12)$ . Sporont finely granulated, filling entire oöcyst. In some oöcysts preserved under coverslip for 24 hours early sign of sporulation was found; in these oöcysts narrow space appeared between thin oöcyst wall and short, ellipsoidal sporont (Figure 7).

Oöcysts pass from gut unsporulated.

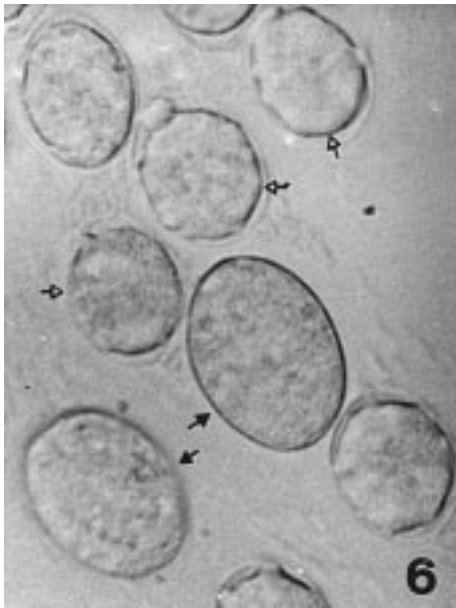


Figure 6. Unsporulated oocysts of *Goussia* sp. II (arrow) and *Goussia* sp. III (open arrow) in the intestinal mucus of *Hemibarbus barbus*.  $\times 1,500$ .

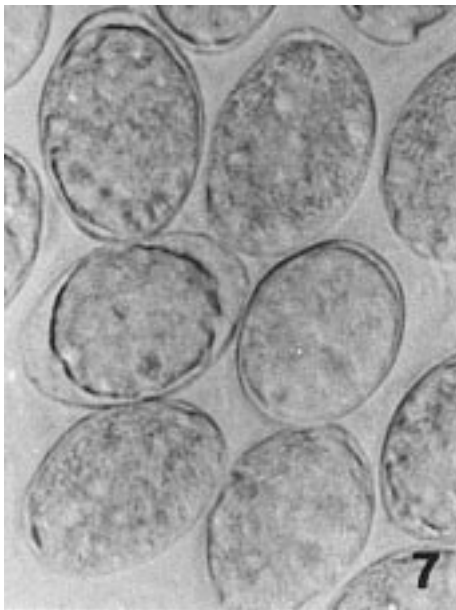


Figure 7. Oocysts of *Goussia* sp. II in the early stage of sporulation. In most of the oocysts there is a space between the sporont and the oocyst wall.  $\times 1,500$ .

### Remarks

The oocysts found resembled those of *G. vargai* Molnár, 1986, a parasite of the sterlet, and *G. balatonica* Molnár, 1989, a parasite of the white bream. Both of these parasites have unsporulated oocysts in the gut, which are also accompanied by oocysts of other smaller species. These two species complete their sporulation in clean tap-water within 24 or 48 days.

### *Goussia* sp. III

*Host:* *Hemibarbus barbus* (Temminck & Schlegel); Cyprinidae.

*Locality:* Mano, Lake Biwa, Shiga Prefecture, Japan.

*Site:* Gut content of the foregut, intestinal mucus and intestinal scrapings.

*Prevalence of infection:* Two infected specimens, 66%.

### Description (Figure 6)

Only unsporulated oocysts were found (Figure 6). Oocysts spherical or short ellipsoidal, measuring 11 (10–12)  $\times$  9 (8–10). Sporont finely granulated, filling entire oocyst. In some oocysts preserved under coverslip for 24 hours early sign of sporulation was found; in these oocysts narrow space appeared between thin oocyst wall and short, ellipsoidal sporont.

Oocysts pass from gut unsporulated.

### Remarks

The oocysts found resembled oocysts of *G. acipenseris* Molnár, 1986, a parasite of the sterlet, *G. pannonica* Molnár, 1989, a parasite of the white bream, *G. janae* Lukeš & Dyková, 1990, a parasite of the dace, *G. desseri* Molnár, 1996, a parasite of the pikeperch, and *G. koertingi* Baska, 1997, a parasite of the common barbel. All these *Goussia* spp. have about the same oocyst size and leave the host intestine unsporulated. The latter species finish their sporulation in clean tap-water within 24 to 48 days.

### Discussion

This survey of Lake Biwa fishes revealed that fishes of the Japanese fauna exhibit a similar infection with coccidian species as fishes from other biotopes. In this study only representatives of the genus *Goussia* were

identified. The majority of previously known fish coccidia identified as *Eimeria*, *Goussia*, *Crystallospora* Labbé, 1896, *Calyptospora* Overstreet, Hawkins & Fournie, 1984 and *Cryptosporidium* Tizzer, 1907 belong to *Eimeria* and *Goussia*. The genus *Goussia* was regarded for a long time as a synonym of *Eimeria*, but it was reinstated by Dyková & Lom (1981), who assigned *Goussia* to the Eimeriidae. Overstreet et al. (1984) included it in the family Calyptosporidae, while Levine (1988) regarded *Goussia* as a member of the family Barrouxiidae. Lom & Dyková (1992) are still of the opinion that *Goussia* should remain in the family Eimeriidae. Sporulated oöcysts of the new species found in this study bear typical *Goussia* characteristics. Although the unsporulated oöcysts of *Goussia* II and III do not permit a definitive diagnosis, the results obtained on unsporulated oöcysts by Molnár (1986, 1989, 1996), Kent et al. (1988), Lukeš & Dyková (1990) and Baska (1997) suggest that the sporulation of these species might result in *Goussia*-type oöcysts.

The host-specificity of fish coccidia is little studied. There is no question that a certain level of specificity exists; however, Paterson & Desser (1982) showed that *Goussia* (*Eimeria*) *iroquoina* Molnár & Fernando, 1974 could be transmitted to another closely related fish host. This means that only oöcysts differing morphologically should be described as new species. The new species of *Goussia* species found in this survey do resemble known species, but differ in minor but important morphological features, such as the shape and size of the sporocysts or the presence or absence of polar granules in the oöcysts.

Oöcysts studied in this survey were first detected in clean intestinal mucus, although they were also found in high numbers in the gut contents. However, in the latter location, it was not easy to demonstrate their presence.

The demonstration of *Goussia*-type oöcysts (*G. wakabayashii* n. sp.) in gobiid fishes appears to be new for fish coccidia, but it is likely that other freshwater gobiids also have *Goussia* infections in the gut (Molnár, unpublished).

The detection of unsporulated oöcysts in the gut of fish deserves special attention, as according to Molnár (1977), Dyková & Lom (1981) and Davies & Ball (1993), the majority of fish coccidia sporulate endogenously. *Goussia* species II and III resemble those described by Molnár (1986, 1989, 1996), Lukeš & Dyková (1990), Kent et al. (1988) and Baska (1997). The above authors found unsporulated oöcysts in the

gut of fishes which sporulated in clean water and were described as new species. In these cases, *G. vargae* Molnár, 1986, *G. balatonica* Molnár, 1989 and a species found by Baska (1997) developed in the fish in certain circumscribed regions of the gut epithelium, while *G. acipenseris* Molnár, 1986, *G. pannonica* Molnár, 1989, *G. janae* Lukeš & Dyková, 1990, *G. girellae* Kent et al., 1988, *G. desseri* Molnár, 1996 and *G. koertingi* Baska, 1997 formed epicellular stages in the gut. In some fish a mixed infection with unsporulated oöcysts was found, and larger oöcysts from nodules and smaller oöcysts from epicellular sites were recorded (Molnár, 1986, 1989). In this respect, the findings reported by Baska (1997) seem to be the most important, as this author found intracellular and epicellular stages in *Barbus barbus* L., a close relative of *Hemibarbus barbus* in which our species with unsporulated oöcysts occurred.

Previously, no method has been developed for preserving fish coccidia and depositing them in collections. Bandoni & Duszynski (1988) and Duszynski & Wilber (1997) suggest that photomicrographs of the sporulated oöcysts should be used for this purpose. Unfortunately, this method, elaborated for the relatively large oöcysts of mammal and avian coccidia, is not suitable for fish coccidia, as these compact small oöcysts with vulnerable oöcyst wall do not resist the cleaning and floatation processes. Efforts by the authors to use this method were rather unsuccessful, as images of oöcysts of the new species with a size in the region of 10 µm proved to be of poor quality.

Although no information on the pathological importance of the coccidia found can be concluded from the data obtained in this survey, the high prevalence and intensity of infection observed in some cases suggests that this group of parasites need more attention.

## References

- Awakura, T., Kojima, H., Sugivaka, K. & Nomura, T. (1983) Studies on parasites of Masu salmon *Onchorhynchus masou*. V. *Eimeria truttae* (Protozoa: Coccidia) found in pyloric caeca. *Scientific Reports of Hokkaido Fish Hatchery*, **38**, 33–38.
- Bandoni, S. M. & Duszynski, D. W. (1988) A plea for improved presentation of type material for coccidia. *Journal of Parasitology*, **74**, 519–523.
- Baska, F. (1997) Epicellular and nodular coccidiosis in the intestine of barbel *Barbus barbus*. *Diseases of Aquatic Organisms*, **29**, 49–56.
- Chen C.-L. (1956a) The protozoan parasites from four species of Chinese pond fishes: *Ctenopharyngodon idellus*, *Mylopharyngodon piceus*, *Aristichthys nobilis* and *Hypophthalmichthys*

- molitrix*. II. The protozoan parasites of *Mylopharyngodon piceus*. *Acta Hydrobiologica Sinica*, **1**, 19–42. (In Chinese).
- Chen C.-L. (1956b) The protozoan parasites from four species of Chinese pond fishes: *Ctenopharyngodon idellus*, *Mylopharyngodon piceus*, *Aristichthys nobilis* and *Hypophthalmichthys molitrix*. III. The protozoan parasites of *Aristichthys nobilis* and *Hypophthalmichthys molitrix*. *Acta Hydrobiologica Sinica*, **2**, 279–299. (In Chinese).
- Chen C.-L. (1973) *An illustrated guide to the fish diseases and causative pathogenic fauna and flora in Hubei Province*. Peking: Science Publishing House, 456 pp. (In Chinese).
- Davies, A. J. & Ball, S. J. (1993) The biology of fish coccidia. *Advances in Parasitology*, **32**, 294–366.
- Dogiel, V. A. (1948) [Parasitic protozoa of fishes from the Peter the Great Bay.] *Izvestiya Gosudarstvennogo Nauchno-Issledovatel'skogo Instituta Ozernogo i Rechnogo Rybnogo Khozyaistva, Leningrad*, **27**, 17–66 (In Russian).
- Dogiel, V. A. & Achmerov, A. Ch. (1959) New species of parasitic protozoa in fishes from River Amur. *Československá Parasitologie*, **6**, 15–25. (In Russian).
- Duszynski, D. W. & Wilber, P. G. (1997) A guideline for the preparation of species description in the Eimeriidae. *Journal of Parasitology*, **83**, 333–336.
- Dyková, I. & Lom, J. (1981) Fish coccidia: Critical notes on life cycles, classification and pathogenicity. *Journal of Fish Diseases*, **4**, 487–505.
- Fujita, T. (1934) Note on *Eimeria* of herring. *Proceedings of the Fifth Pacific Scientific Congress*, **5**, 4,135–4,139.
- Kent, M. L., Fournie, J. W., Snodgrass, R. E. & Elston, R. A. (1988) *Goussia girellae* n. sp. (Apicomplexa, Eimeriorina) in the opaleye, *Girella nigricans*. *Journal of Protozoology*, **35**, 287–290.
- Levine, N. D. (1988) *The protozoan phylum Apicomplexa*. Vol. 1. Boca Raton, Florida: CRC Press, 230 pp.
- Li, L.-X. & Nie, D.-S. (1995) Notes on two species of coccidia from intestine of *Cyprinus carpio*. *Transactions of Researches on Fish Diseases*, **2**, 102–108.
- Lom, J. & Dyková, I. (1992) *Protozoan parasites of fishes*. Developments in Aquaculture and Fisheries Science, Vol. 26. Amsterdam: Elsevier, 315 pp.
- Lukeš, J. & Dyková, I. (1990) *Goussia janae* n. sp. (Apicomplexa, Eimeriorina) in dace *Leuciscus leuciscus* and chub *L. cephalus*. *Diseases of Aquatic Organisms*, **8**, 85–90.
- Molnár, K. (1977) Comments on the nature and methods of collection of fish coccidia. *Parasitologia Hungarica*, **10**, 41–45.
- Molnár, K. (1986) Occurrence of two new *Goussia* species in the intestine of the sterlet (*Acipenser ruthenus*). *Acta Veterinaria Hungarica*, **34**, 169–174.
- Molnár, K. (1989) Nodular and epicellular coccidiosis in the intestine of cyprinid fishes. *Diseases of Aquatic Organisms*, **7**, 89–95.
- Molnár, K. (1996) Nodular coccidiosis of the pikeperch *Stizostedion lucioperca* and Volga perch *Stizostedion volgensis*. *Diseases of Aquatic Organisms*, **27**, 137–180.
- Mori, S. & Miura, T. (1990) List of plant and animal species living in Lake Biwa. *Memoirs of the Faculty of Science, Kyoto University, Series of Biology*, **14**, 13–32. (In Japanese).
- Overstreet, R. M., Hawkins, W. E. & Fournie, J. W. (1984) The coccidian genus *Calyptospora* n. g. and family Calyptosporidae n. fam. (Apicomplexa) with members infecting primarily fishes. *Journal of Protozoology*, **31**, 332–339.
- Paterson, W. B. & Desser, S. S. (1982) The biology of two *Eimeria* species (Protista: Apicomplexa) in their mutual fish hosts in Ontario. *Canadian Journal of Zoology*, **60**, 764–775.
- Su X.-Q. & Chen C.-L. (1987) Three new species of *Eimeria* parasites from freshwater fishes in Hubei province. *Acta Zootaxonomica Sinica*, **12**, 10–15. (In Chinese).
- Shulman, S. S. & Zaika, V. E. in Shulman, S. S. & Shtein, G. A. (1962) Phylum Protozoa. In: Bykhovskii, B. E. (Ed.) [*Key to the parasites of freshwater fish of the USSR*.], Leningrad: Nauka, pp. 7–197. (In Russian).
- Tokumori, H., Murakami, G. & Muroga, K. (1985) The coccidial parasites found in the intestine of cultured carp. *Fish Pathology*, **20**, 505–506.